Hyperinsulinism
Germany · International

# Surgery in Congenital Hyperinsulinism-less *may be* more

Winfried Barthlen

Hyperinsulinism
Germany · International

# congenital hyperinsulinism

- very rare (1:40.000)
- uncontrolled insulin secretion
- life threatening hypoglycemia

# symptoms

- unconsciousness, apathia, fits,
- severe neurological damage

# Genetics

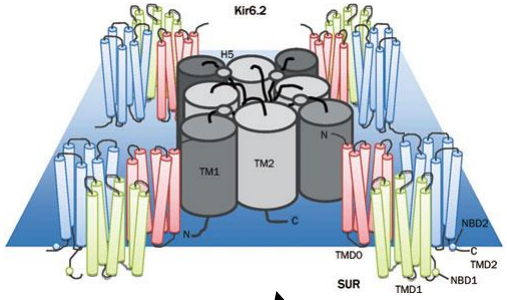


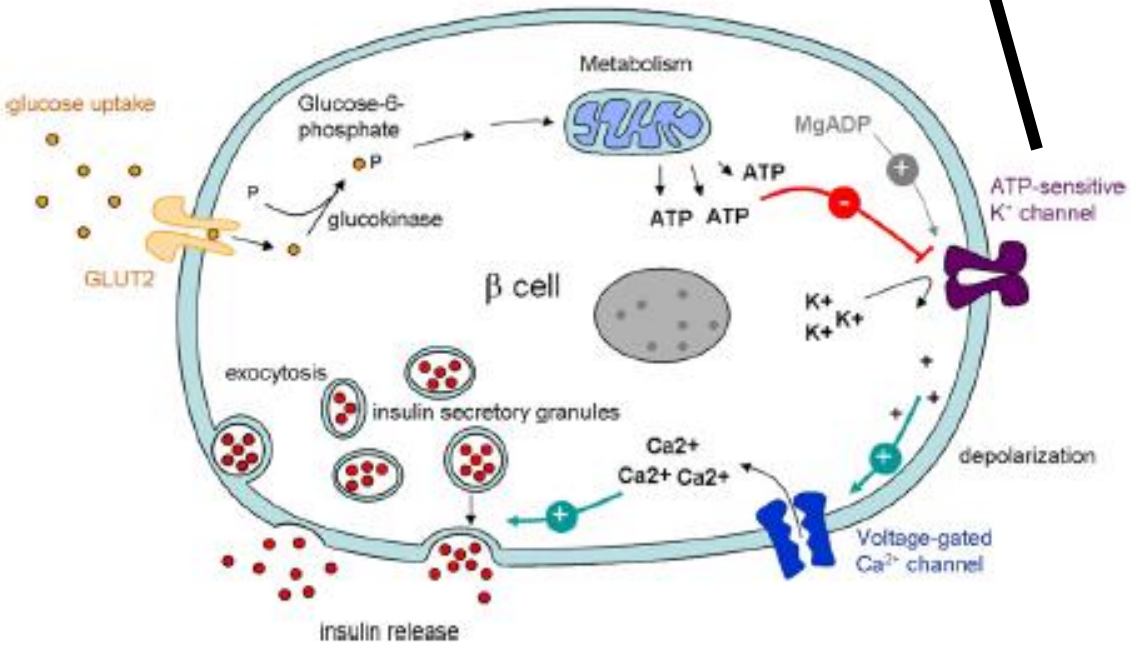


ABCC8
KCNJ11 } 45%

GCK
GLUD1
HADH
HNF1A
HNF4A } 10%
UCP2
SLC16A1

Saint-Martin 2011, Senniappan 2012

# CHI forms

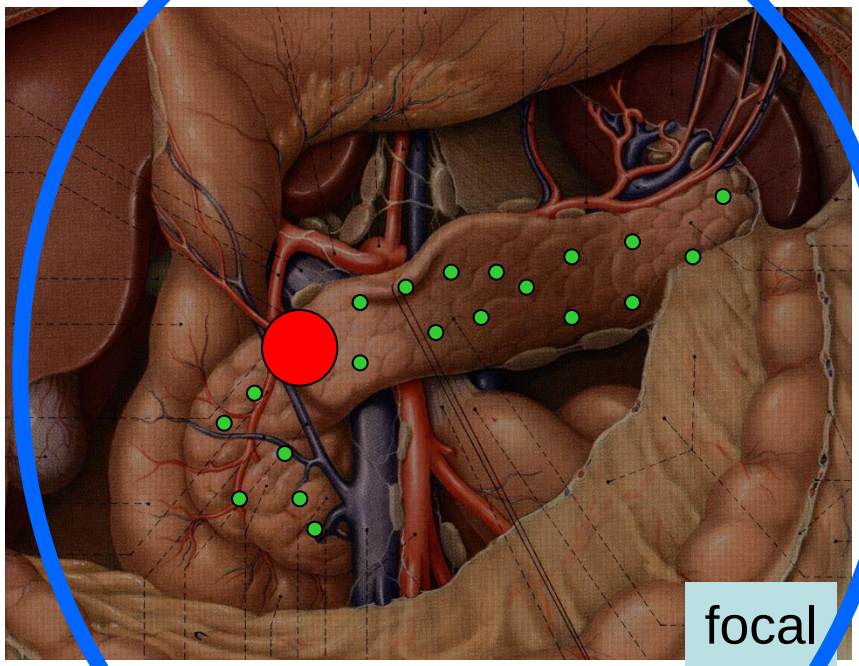


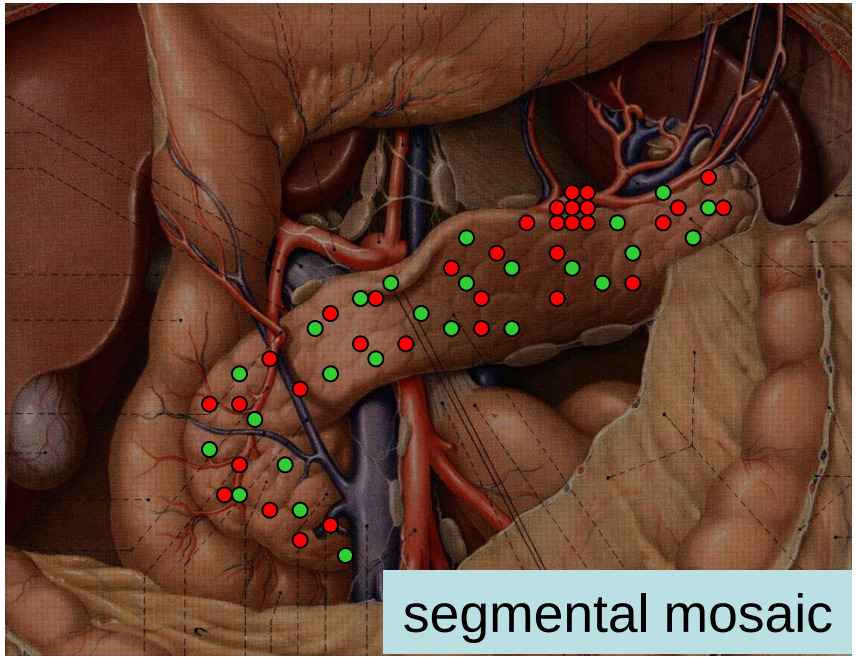


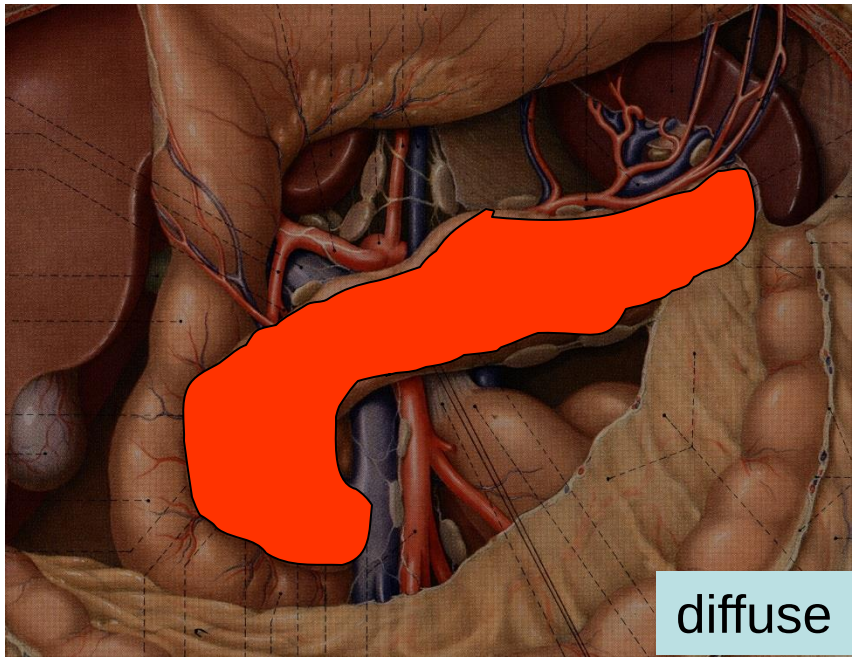


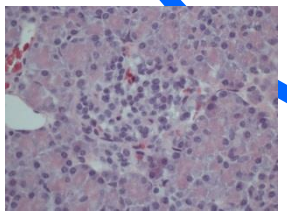

normal islets

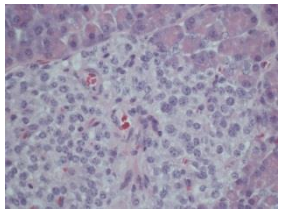

pathological islets

# *Focal* CHI:

-paternal mutation in ABCC8 or KCNJ11
-maternal loss of heterozygosity (LOH) only in the focal lesion

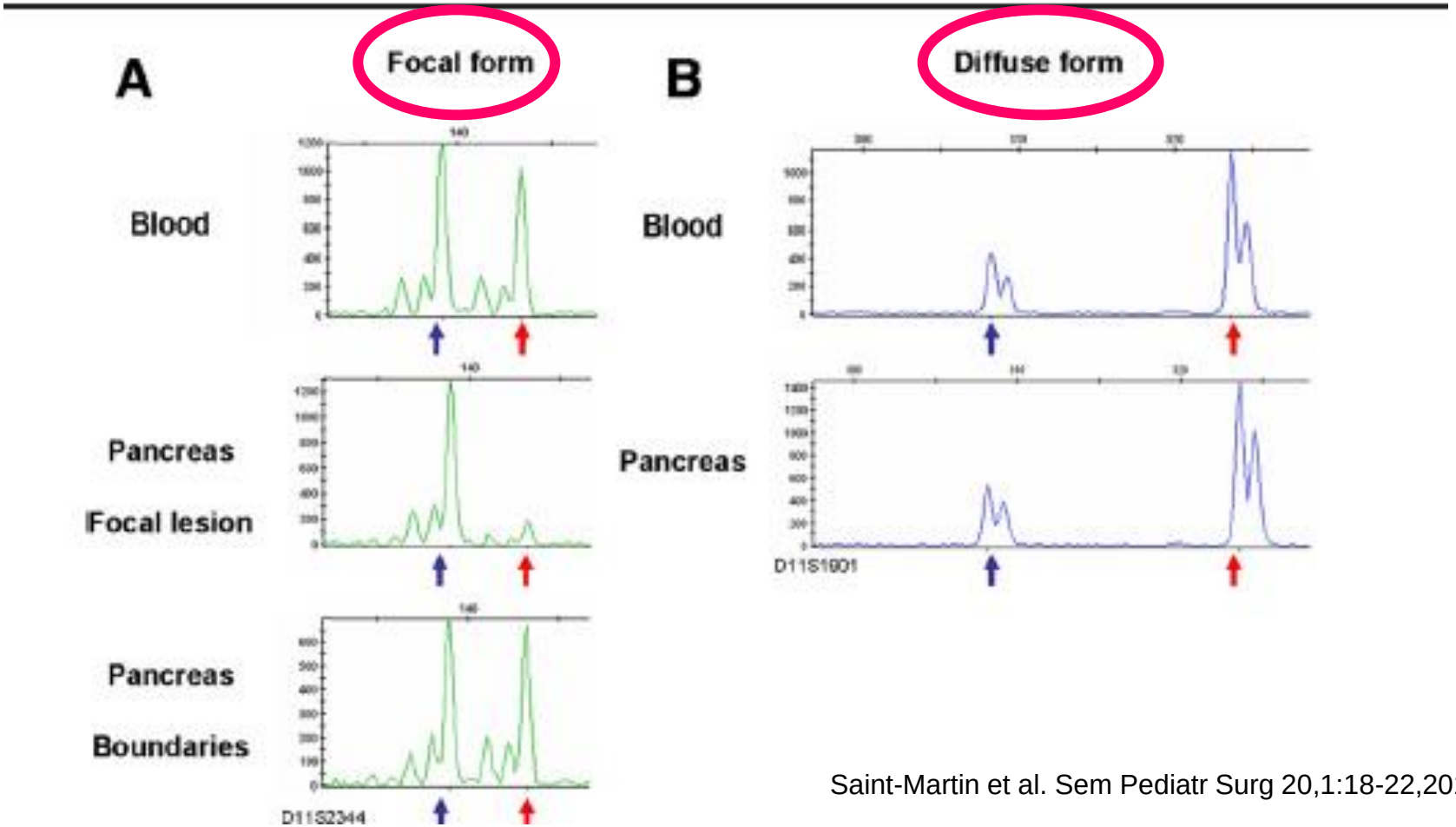


Saint-Martin et al. Sem Pediatr Surg 20,1:18-22,2011

# Josip,6 months $^{18}$F- DOPA- PET/CT


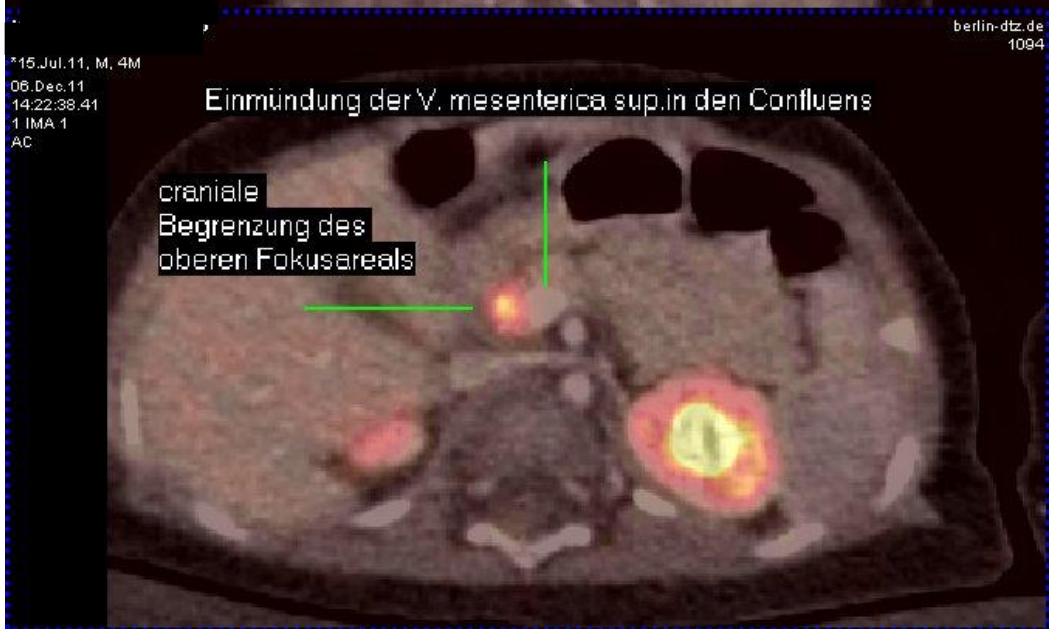


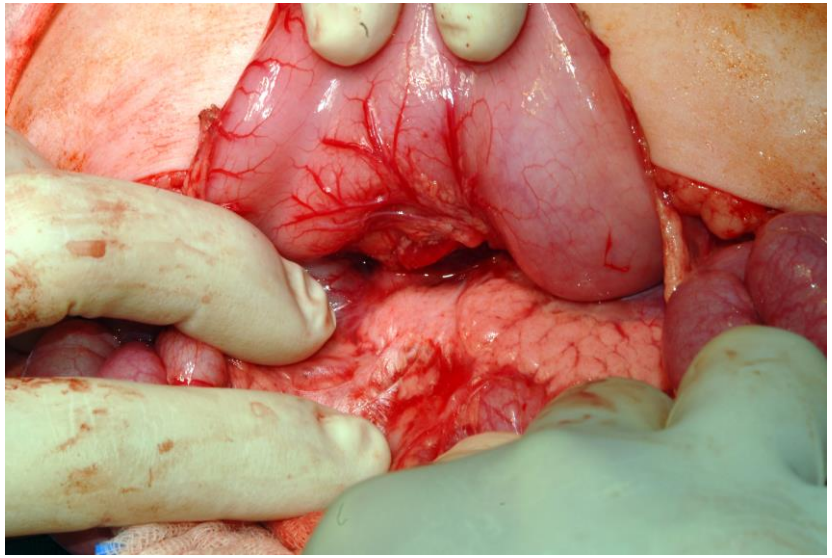

# frozen sections during surgery

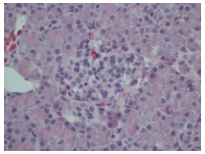

normal

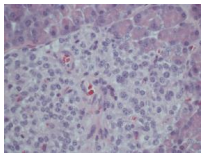

pathological


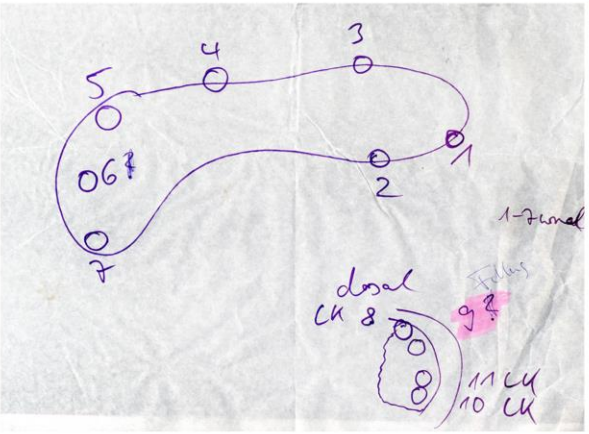

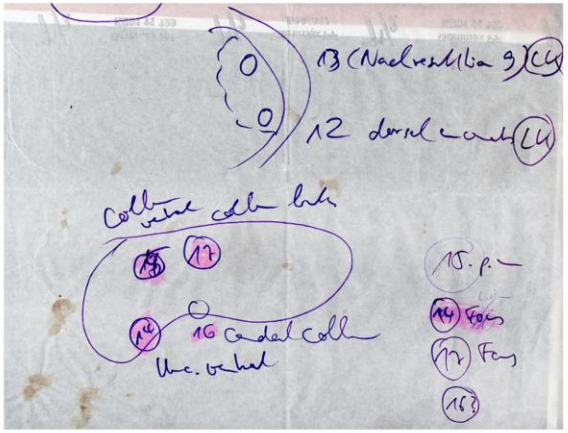

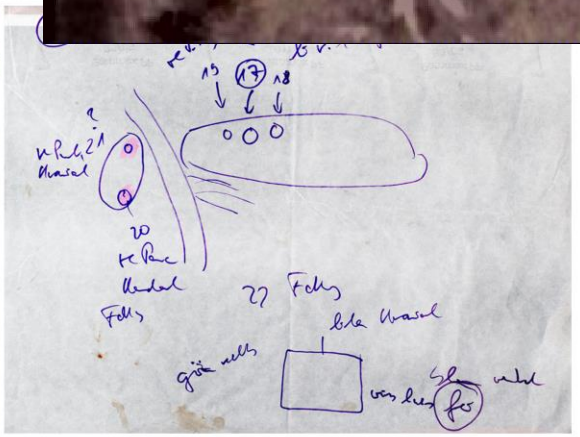

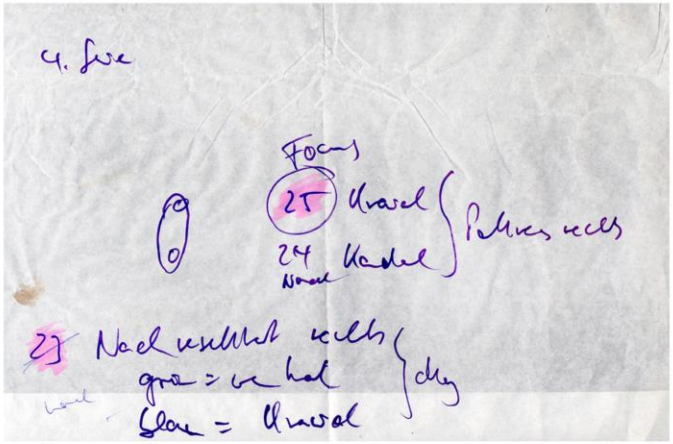

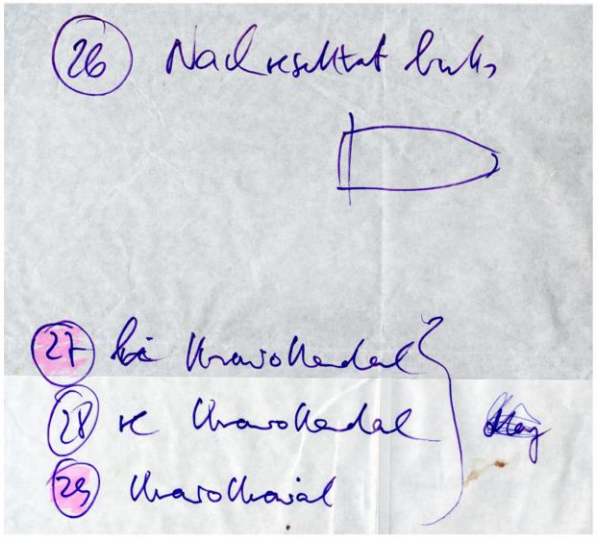

Josip: n = 29

Barthlen

# Josip, 6 Monate

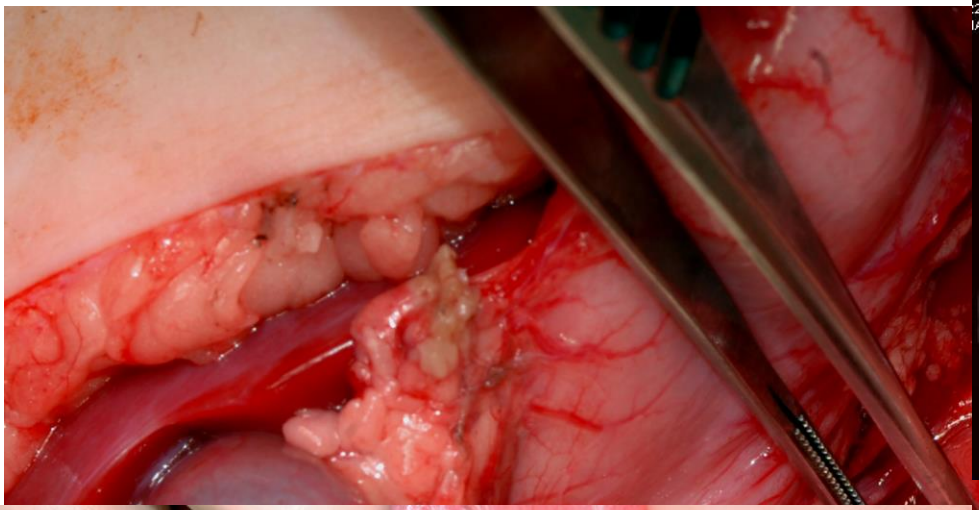


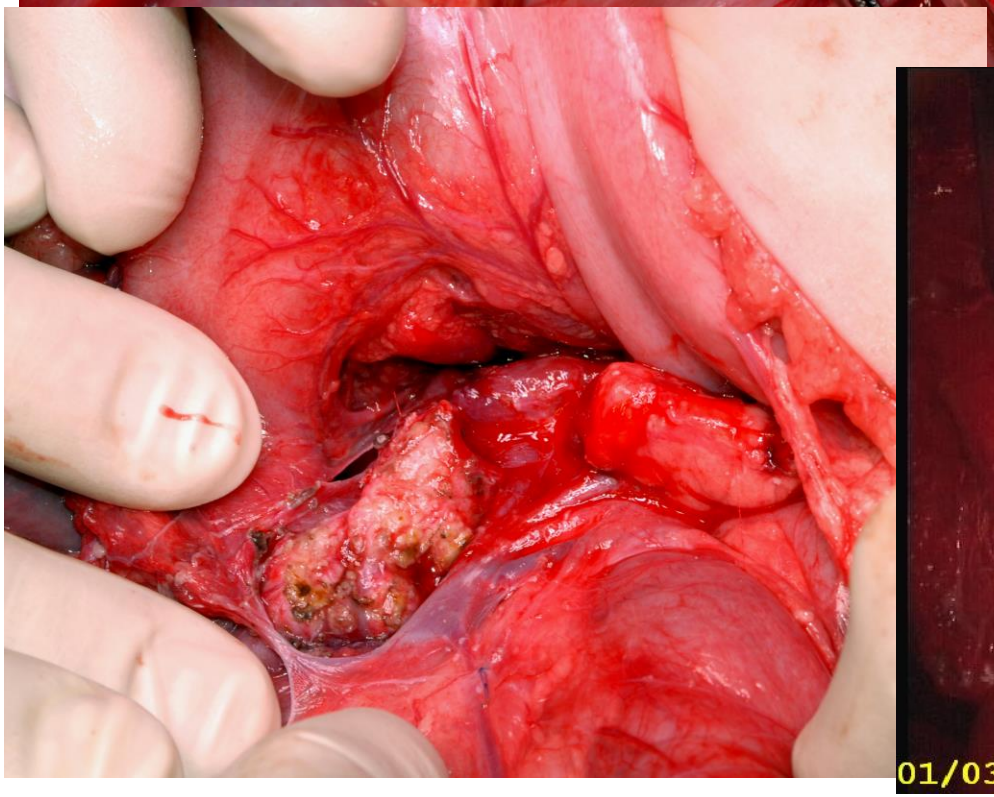

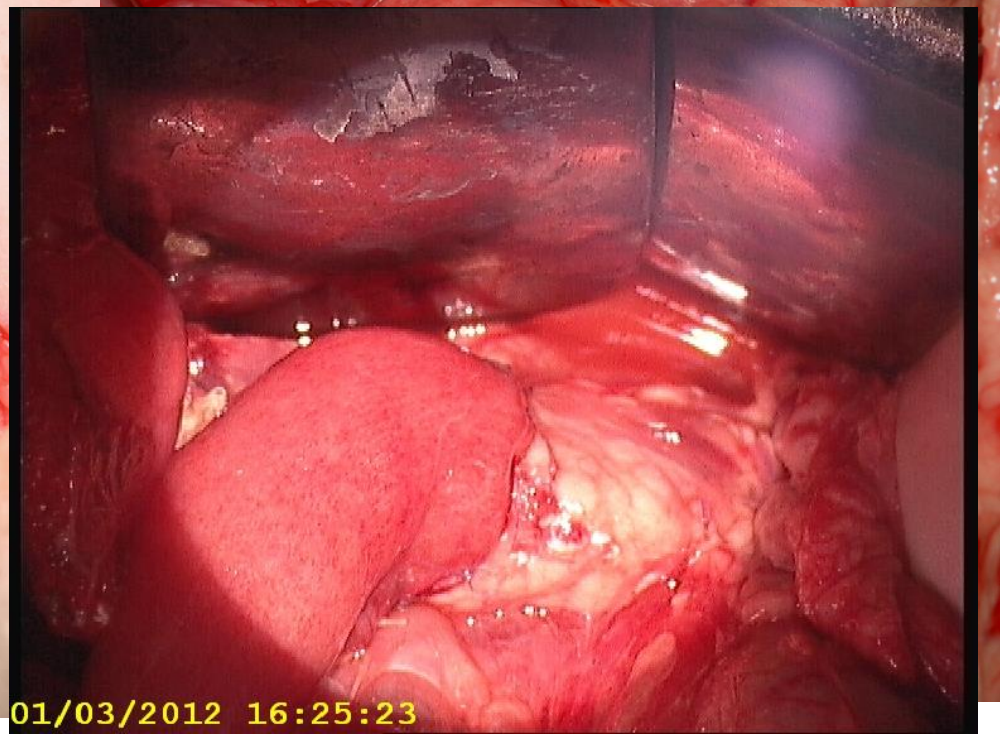

# Ashton from Malaysia, 17 months old

pat

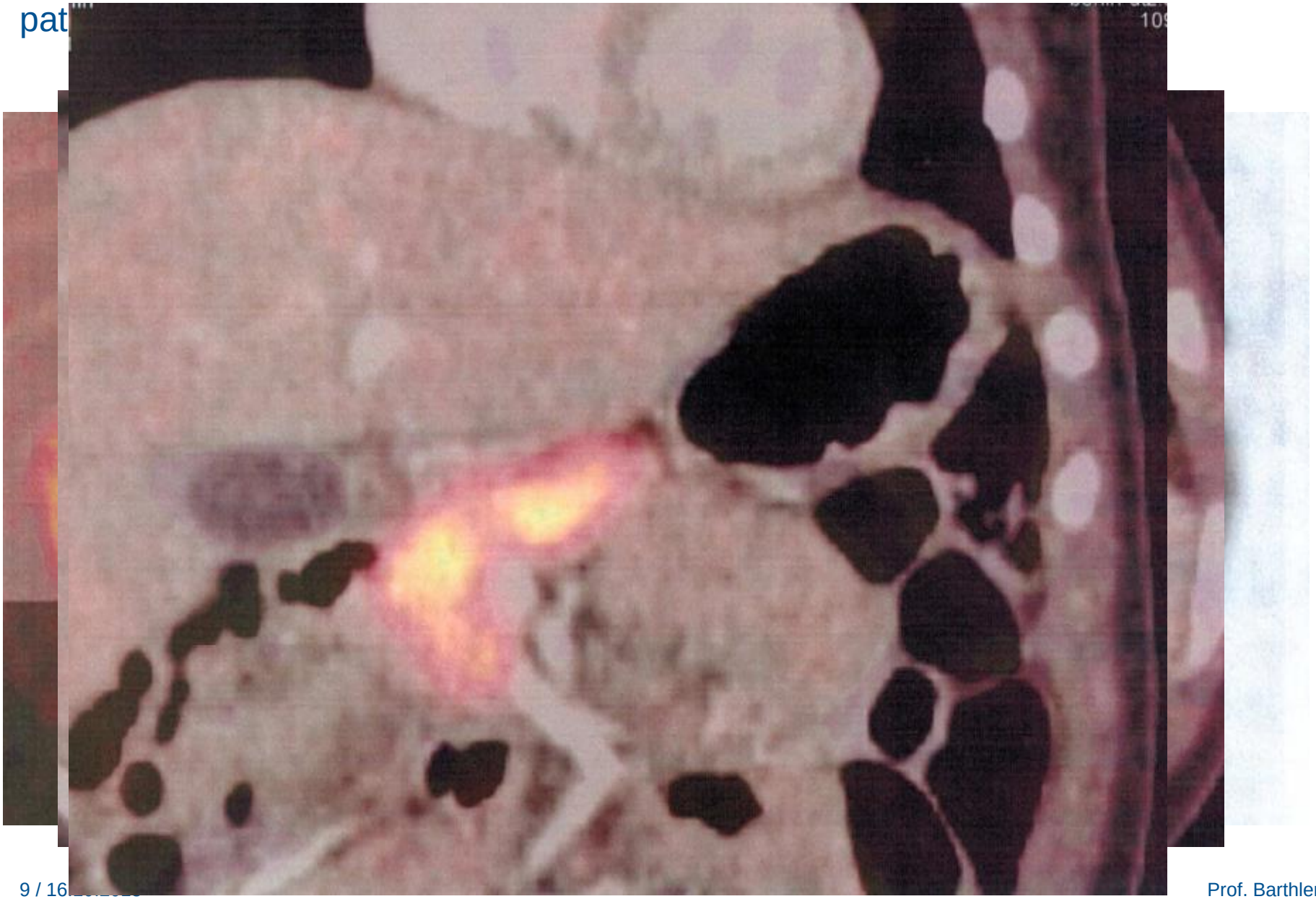

# Ashton

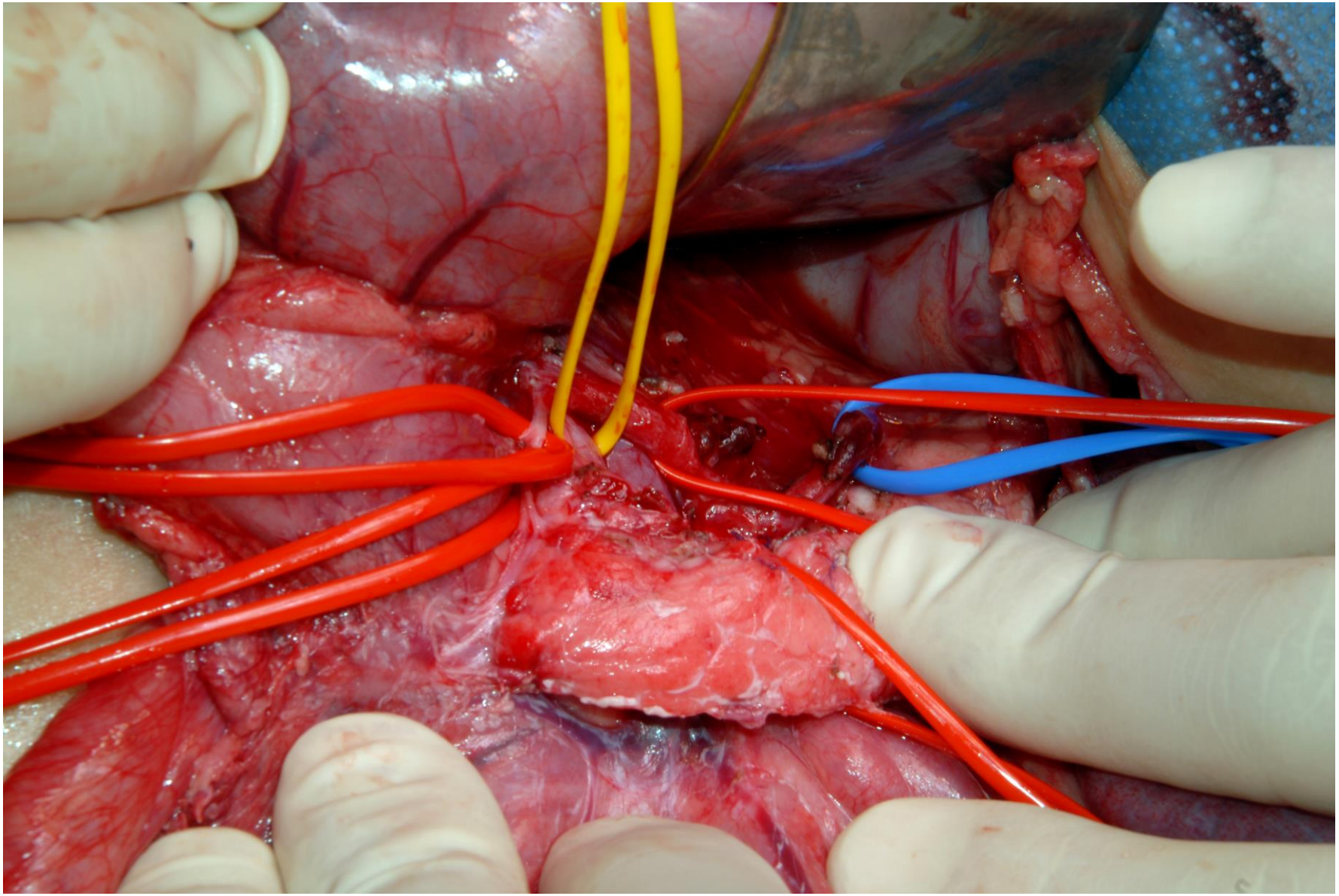

choledochal duct - gastroduodenal,hepatic, lienal artery

# Ashton

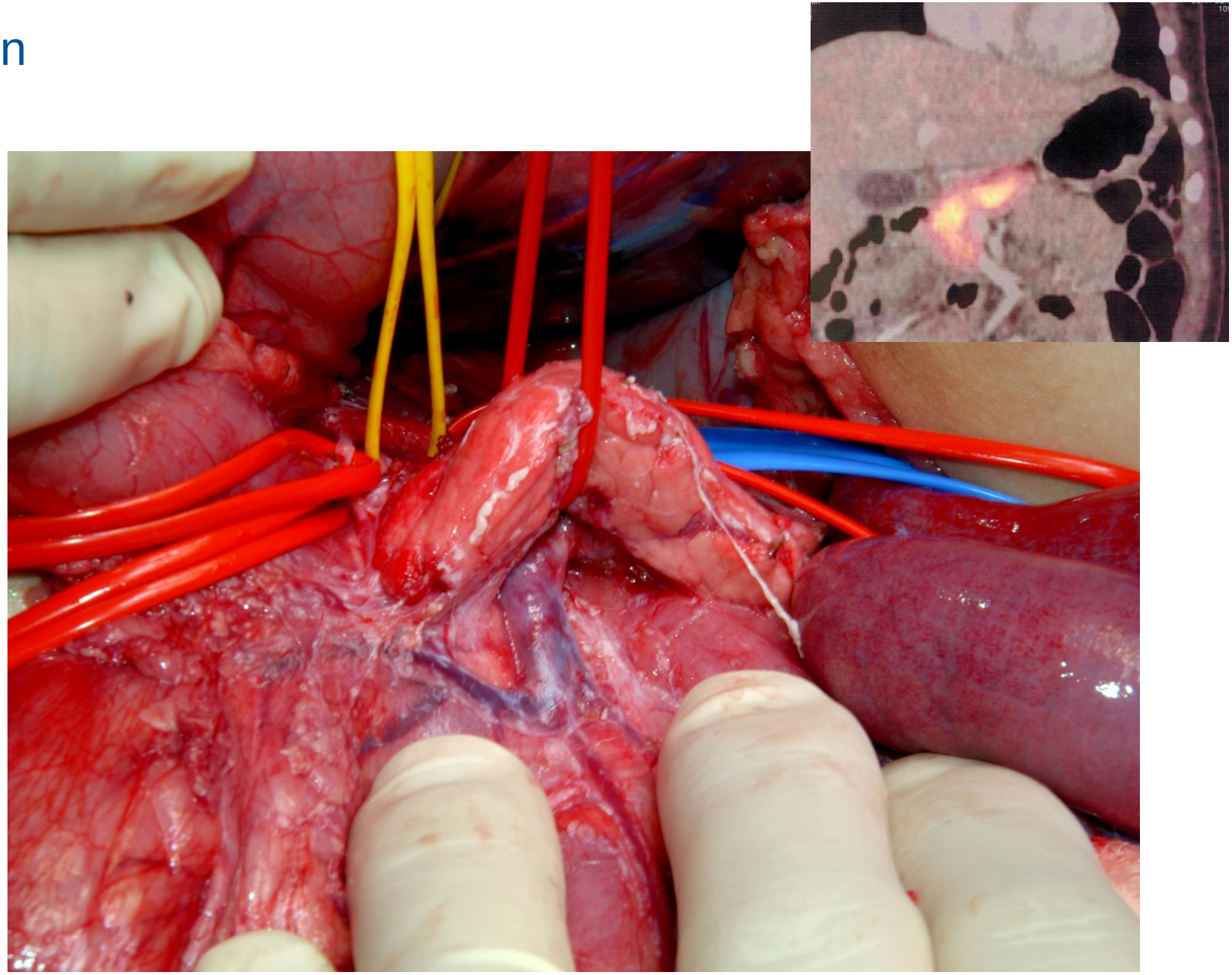

venous
confluens

# personal series *focal* CHI

| n = 42 | Charité Berlin<br>2004-2008 | Greifswald 2010 - today |
|---|---|---|
| focal | 22 | 20 |
| focal lesion visible and palpable | 1 | 0 |
| cured | 19 (86%) | 19(95%) |
| 2nd surgery<br>3rd surgery | 3 | 1<br>1 |
| laparoscopy | 3 | 9 |
| Roux-en-Y | 4 | 6 |
| complications | 1 pseudocyst | **1 pulmonary embolism (factor V Leiden mutation)**<br>**1 adhesion ileus, 1 NEC** |

**Asyraf from Malaysia, 6 months**
**three surgeries August 2013**

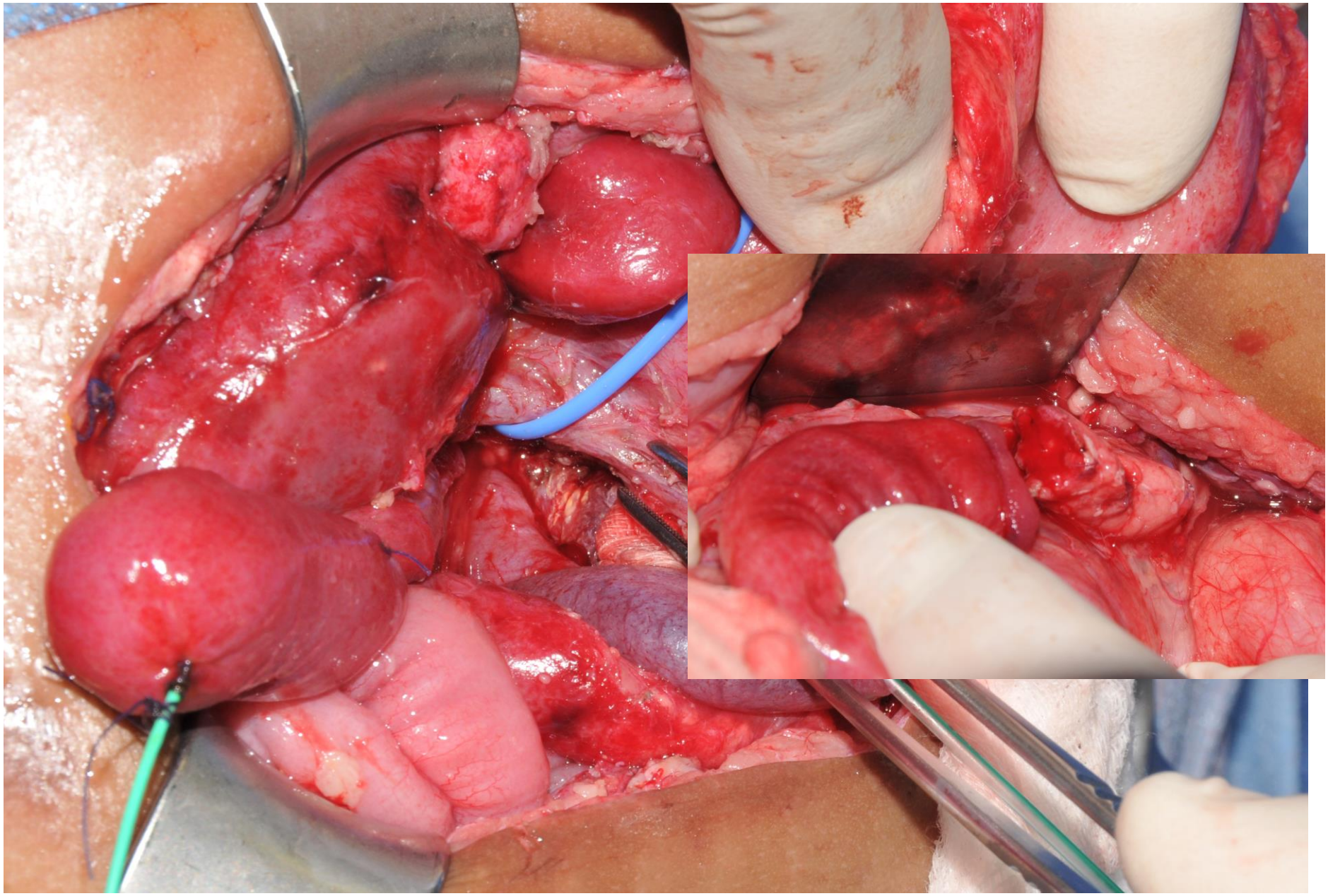

# CHI forms

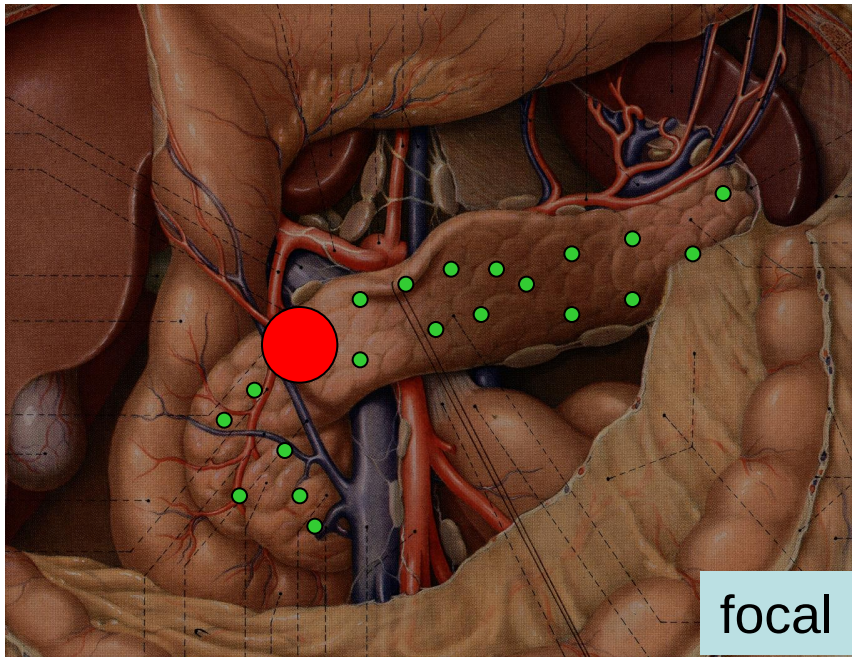


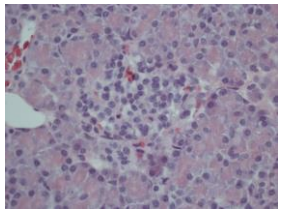

normal islets

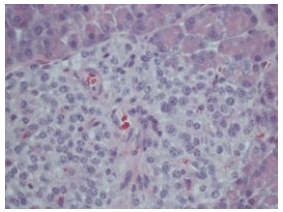

pathological islets

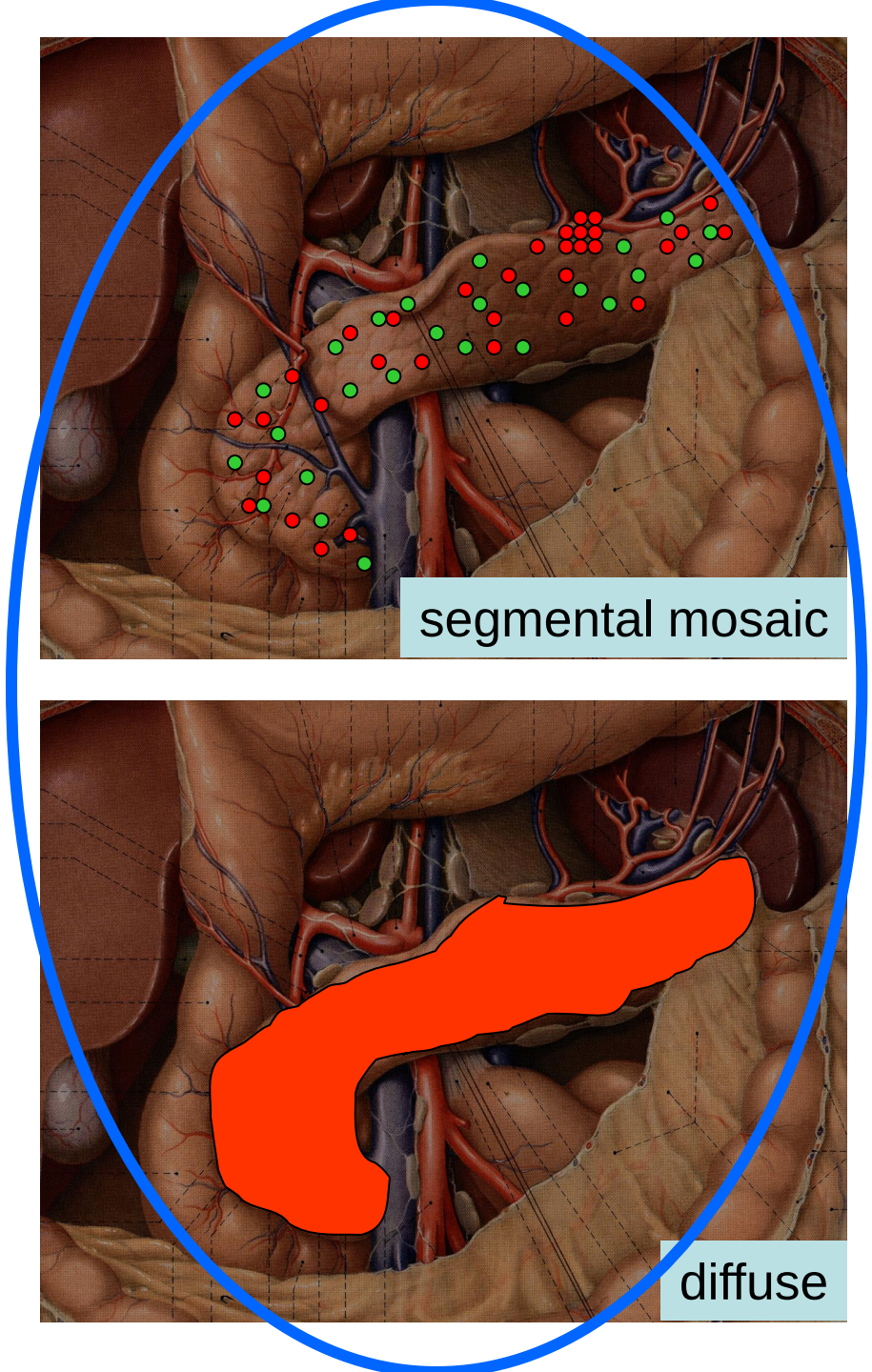

persisting hypoglycemia
(< 50 mg/dL or < 2.8 mmol/L)

## Laboratory

simultaneous blood taking for
blood glucose, insulin, ß-hydroxybutyrat, fatty acids

## Differential diagnoses

- transient hypoglycemia of the newborn
- diabetes mellitus of the mother
- hypopituitarism, cortisol deficiency
- etc.

## Diagnosis: congenital hyperinsulinism

hypoglycemia and normal or elevated insulin levels, low ß-hydroxybutyrate, free fatty acids,
glucose demand >8mg/kg/min; glucagon testing: rise in blood glucose > 30 mg/dL,

**Diazoxide**
5-15 mg/kg/day

+ → Long term therapy (for years)

- → **Genetics**
ABCC8, KCNJ11, GK, GLUD1, HADH, SLC16A1, HNF4A, UCP2

- ↓

**Octreotide**
15-50µg/kg/day

+ → Long term therapy (for years)

- ↓

**Glucagon**
1-2 mg/day

**unresponsive ?**

lap. pancreatic biopsy
lap. restrictive pancreatic resection

non-focal

$^{18}$F-DOPA-PET/CT

focal CHI → selective surgical resection of the focal lesion

Arnoux 2011

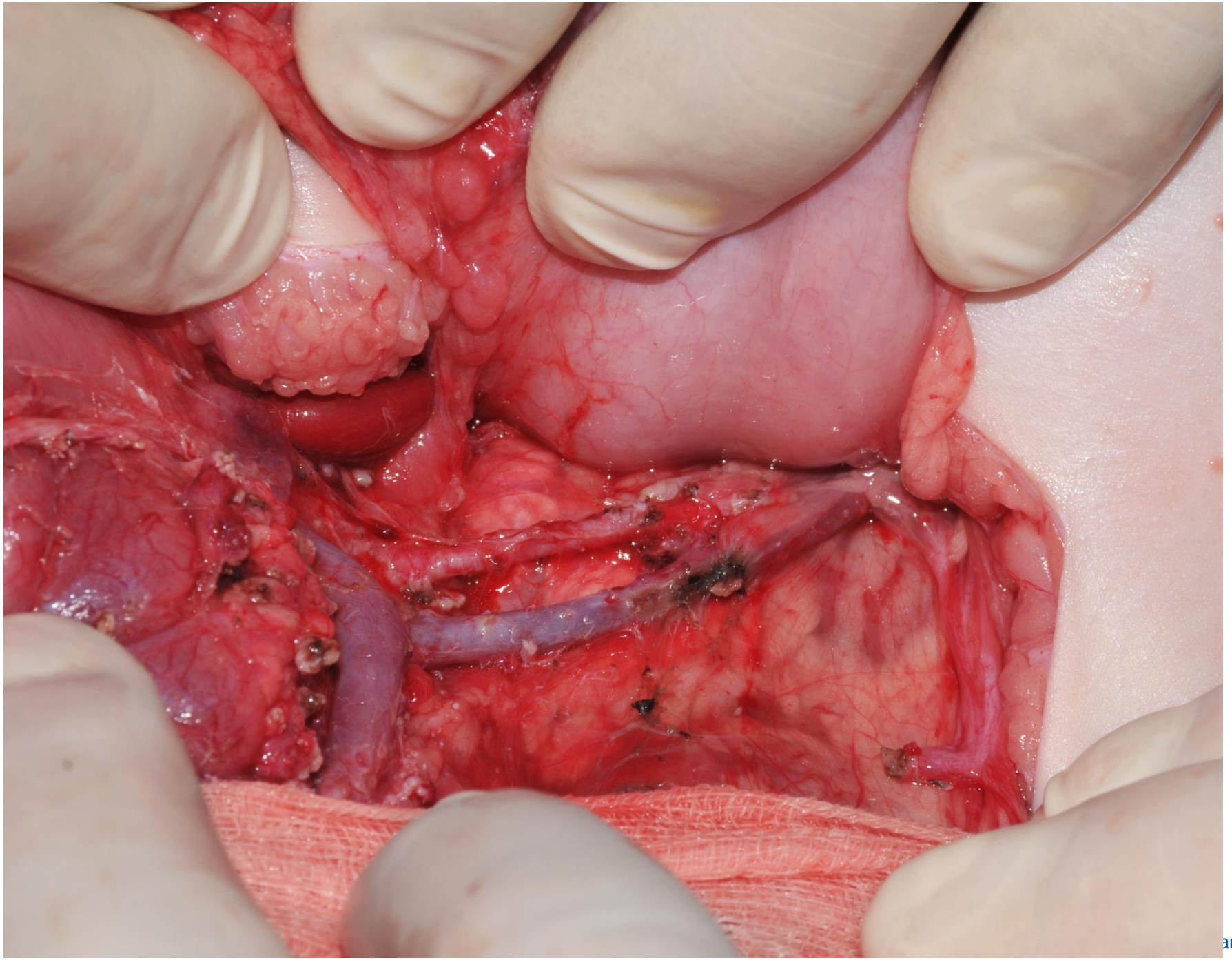

arthlen

# subtotal pancreatectomy: long term results:

## *diabetes*

19% postop

~~42% at 8 yrs~~

***91% at 14 yrs***

n=58
1984-2006
Hopital Necker Paris

Beltrand, de Lonlay et al
*Diabetes Care 2012*

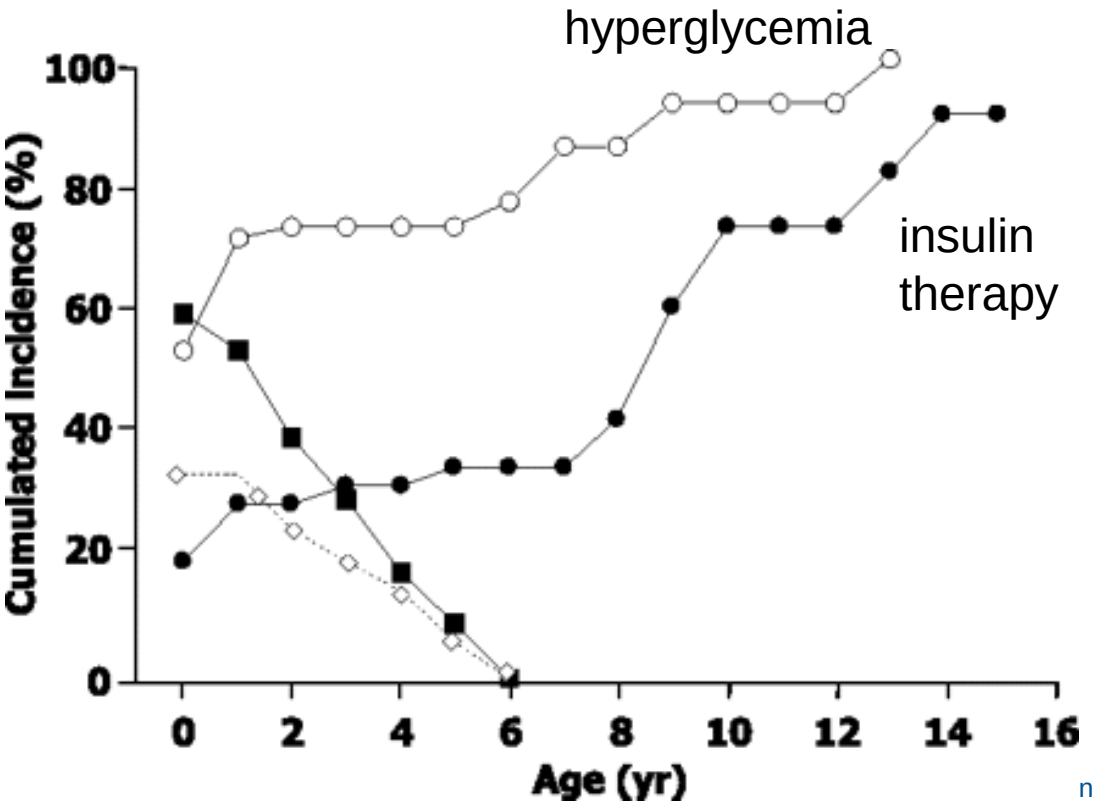

J Clin Endocrinol Metab, December 2011, 96(12):3785–3793

# Morphological Mosaicism of the Pancreatic Islets: A Novel Anatomopathological Form of Persistent Hyperinsulinemic Hypoglycemia of Infancy

C. Sempoux, C. Capito, C. Bellanné-Chantelot, V. Verkarre, P. de Lonlay, Y. Aigrain, C. Fekete, Y. Guiot, and J. Rahier

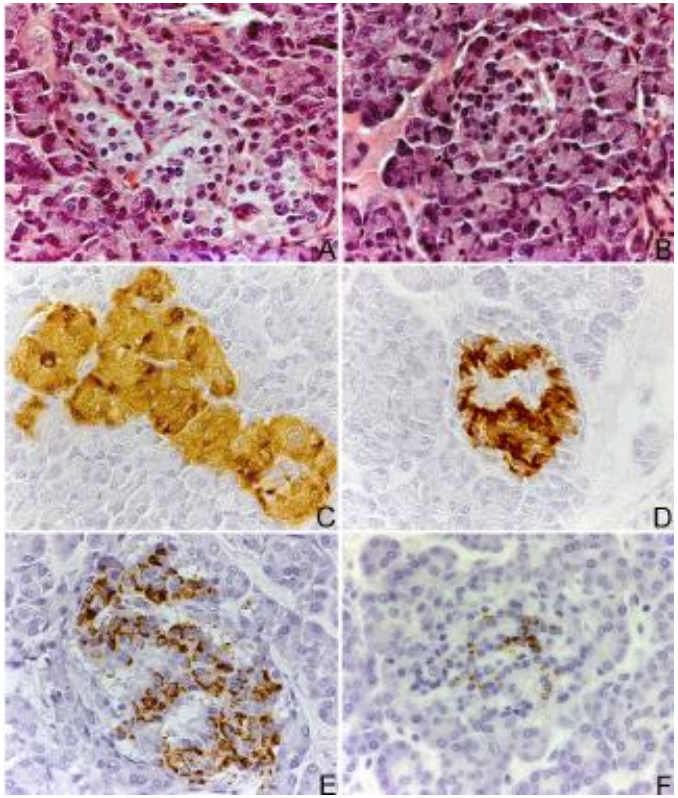


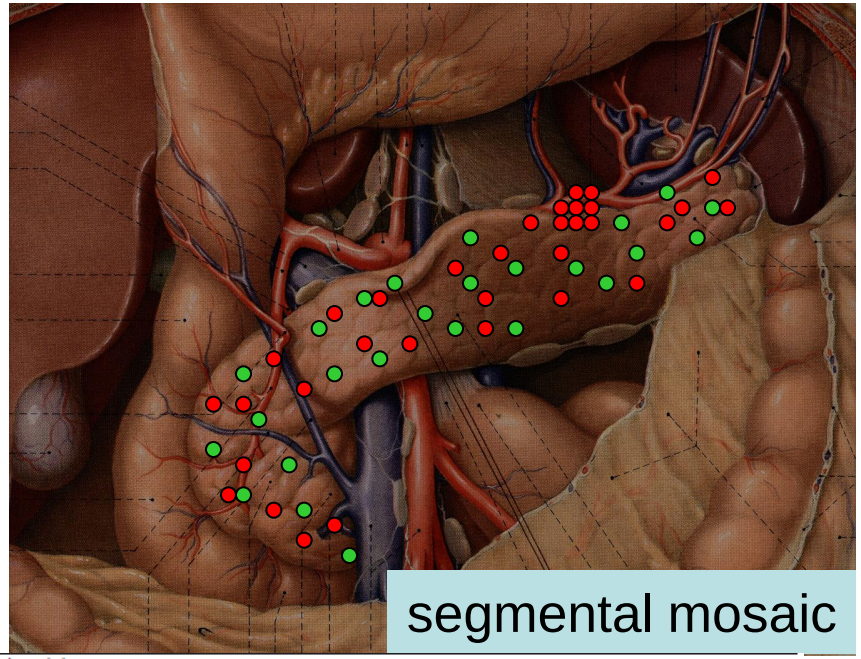


**TABLE 1.** Clinical data

| Case | Sex | Birth weight (percentile) | Age at presentation (months) | Preop Dzx treatment (mg/kg · d) | Localization (PVS or $^{18}$F-PET) | Surgery | Follow-up |
|---|---|---|---|---|---|---|---|
| 1 | F | 46 | 3 | 6.5 | Inconclusive (PVS) | Partial tail | Recurrence controlled by low-dose Dzx |
| 2 | F | 78 | 6 | 10 | Focal-corpus (PVS) | Partial corpus and tail | Cured |
| 3 | M | 94 | 8 | 10 | Focal (PVS) | Partial corpus and tail | Cured |
| 4 | F | 4 | 5 | 12 | Diffuse (PVS) | Partial corpus and tail | Cured |
| 5 | F | 64 | 6 | 15 | Focal-tail (PVS) | Partial tail | Cured |
| 6 | F | 69 | 3 | Sensitive to Dzx | Focal (PVS) | Partial corpus and tail | Cured |
| 7 | M | 79 | 4 | Transient sensitivity | Tail (PVS) | Tail | Cured |
| 8 | M | 48 | 5 | 15 | Focal-head (PVS) | Partial | Recurrence controlled by low-dose Dzx |
| 9 | M | 7 | 9 | 10 | Focal tail (PVS) | Partial tail | Cured |
| 10 | M | 40 | 5.5 | 12 | Focal tail (PVS) | Partial tail | Recurrence controlled by low-dose Dzx |
| 11 | F | 51 | 6 | 6 | Focal tail (PVS) | Partial corpus and tail | Cured |
| 12 | F | 86 | NN | Transient sensitivity | Focal corpus (PVS) | Partial corpus and tail | Cured |
| 13 | M | 48 | 4 | 18 | Focal corpus and tail (PVS) | Partial corpus and tail | Cured |
| 14 | F | 90 | NN | 15 | Inconclusive (PVS) | Head corpus and tail | Recurrence controlled by low-dose Dzx |
| 15 | F | Unknown | 6 | Sensitive to Dzx | Inconclusive ($^{18}$F-PET) | Partial head and isthmus | Recurrence controlled by low-dose Dzx |
| 16 | M | 45 | 7 | Transient sensitivity | Inconclusive (PVS and $^{18}$F-PET) | Corpus and tail | Recurrence controlled by low-dose Dzx |

Cases 4, 6, and 13 were not tested for *ABCC8*, *KCNJ11*, and *GCK* mutations. Mutations in the *GDH* gene have been ruled out in [illegible], 10, and 14. Dzx, Diazoxide; F, female; M, male; Preop, preoperative.

Jolina, 15 months
medically unresponsive

laparoscopic biopsies:
segmental mosaic CHI

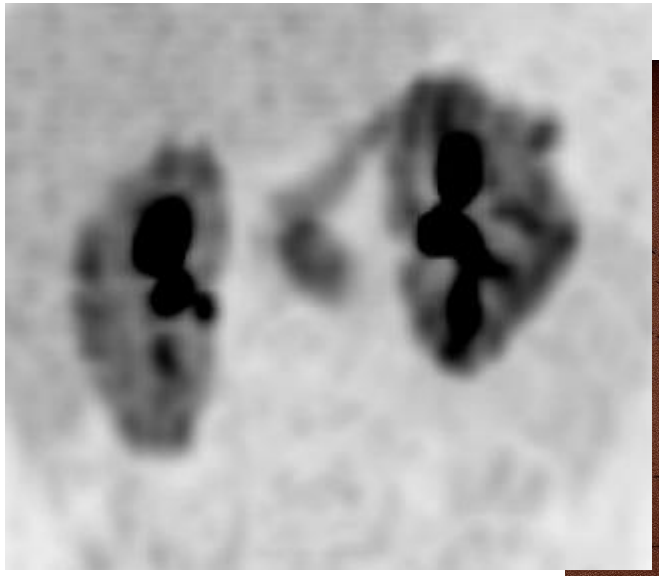

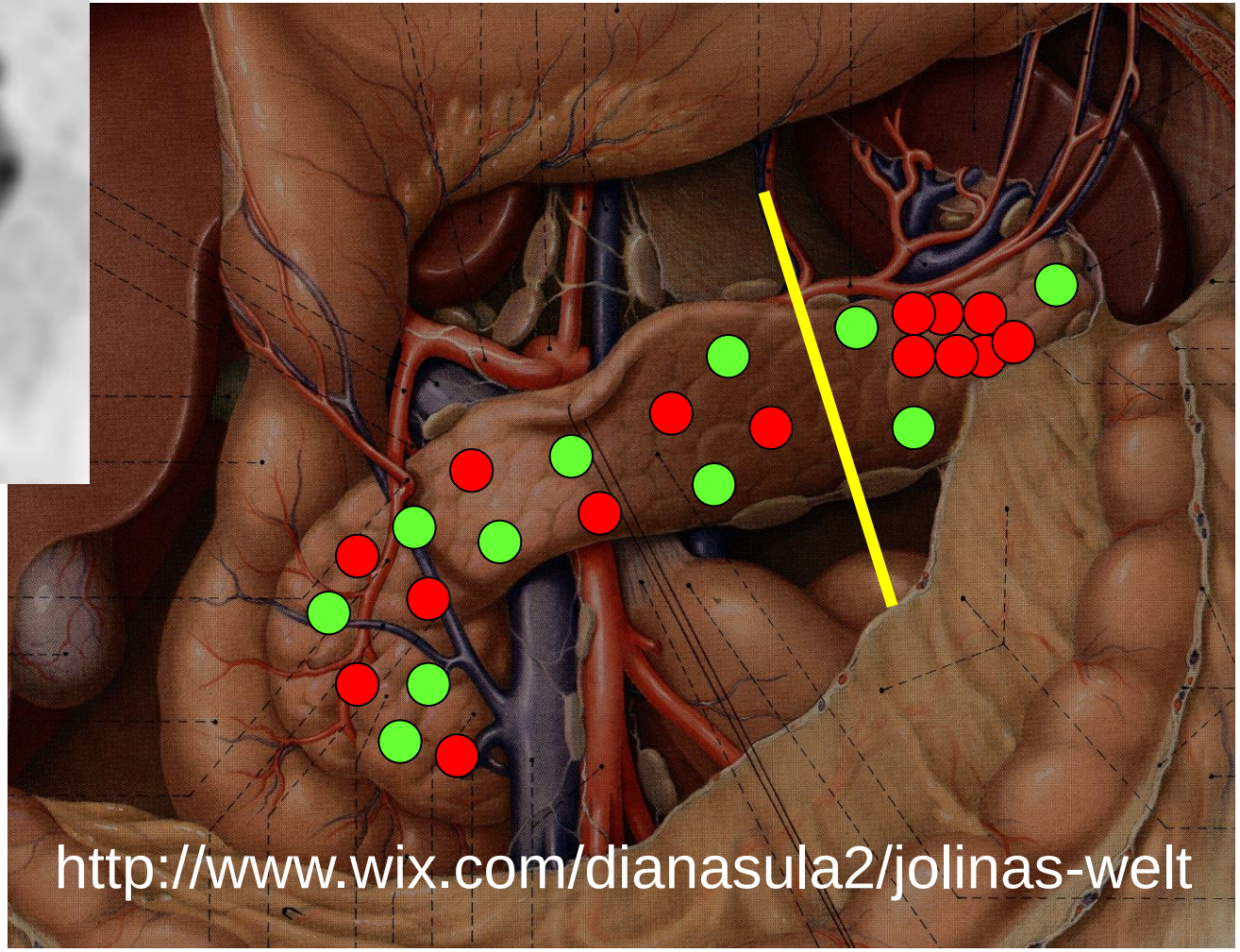

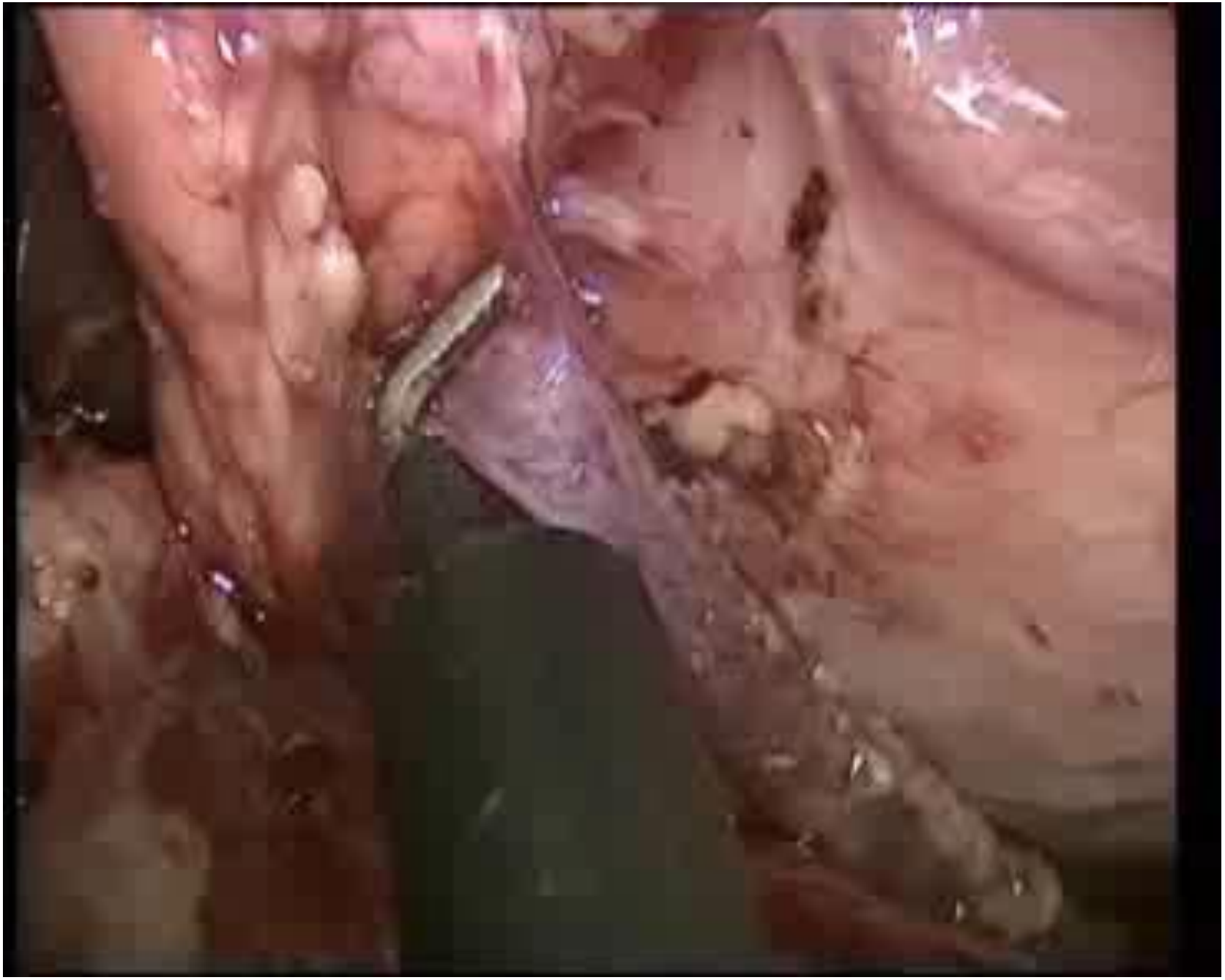

Laparoscopic pancreatic tail resection

# Lota from Croatia, 9 months

# restrictive surgery in *segmental mosaic* CHI

| pat | age at diagnosis (months) | mutation | medication before surgery | response to medication | age at surgery (months) | medication after surgery | time follow-up (september 2013) |
|---|---|---|---|---|---|---|---|
| JB | 6 | none | diazoxide 7mg/kg/d | un-satisfactory | 15 | none | 31 |
| LH | 5 | none | diazoxide 7.5mg/kg/d | insufficient | 15 | diazoxide 7.1 mg/kg/d | 26 |
| FS | 3 | none | diazoxide 22mg/kg/d and octreotide 15μg/kg/d | insufficient | 18 | diazoxide 8.8 mg/kg/d | 25 |
| HB | 3 | ABCC8 compund heterozygous | octreotide 17 μg/kg/d and glucagon 11 μg/kg/h | insufficient | 10 | lanreotide 60mg/month | 9 |

complications n=0

# Results *segmental mosaic* CHI

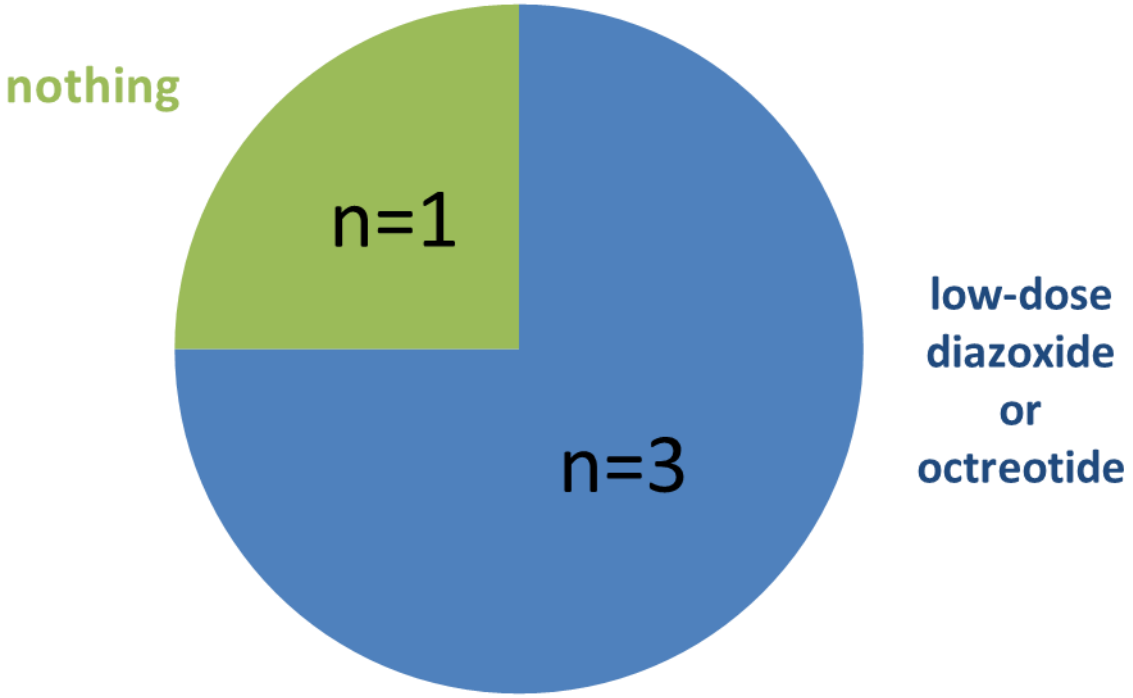


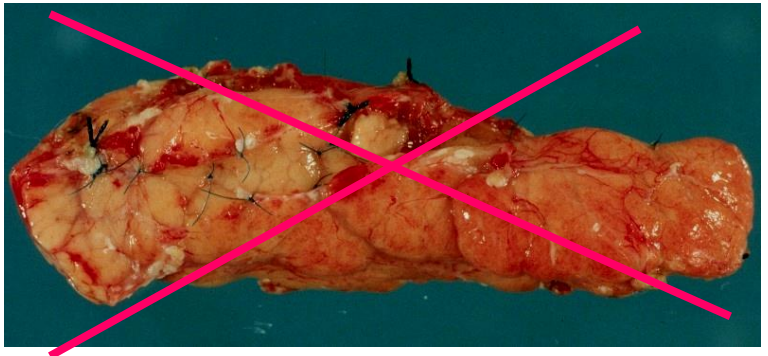

# CHI forms

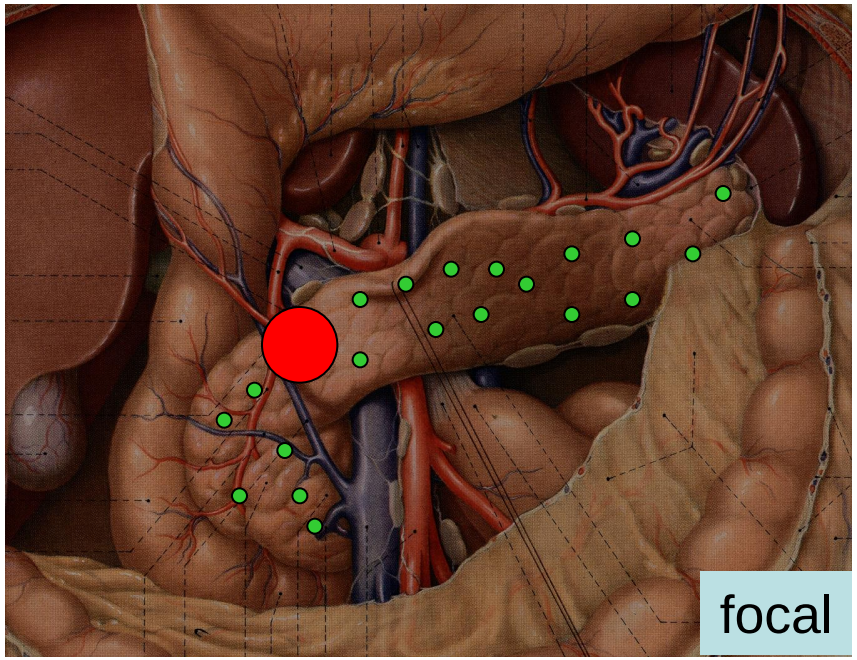


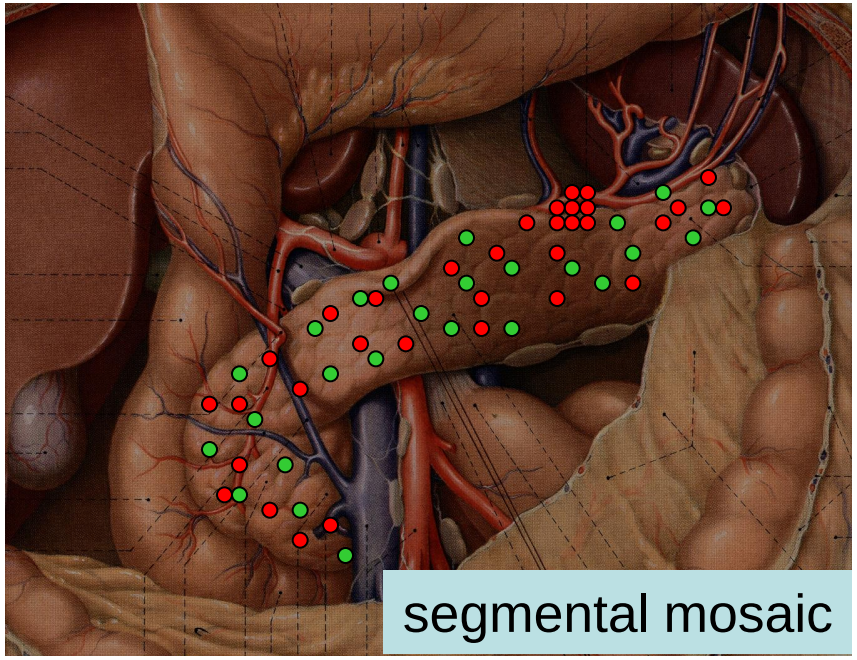


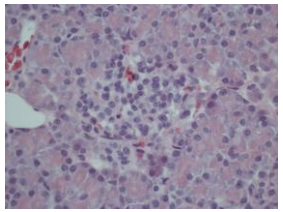

normal islets

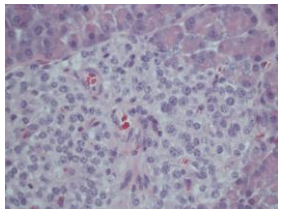

pathological islets

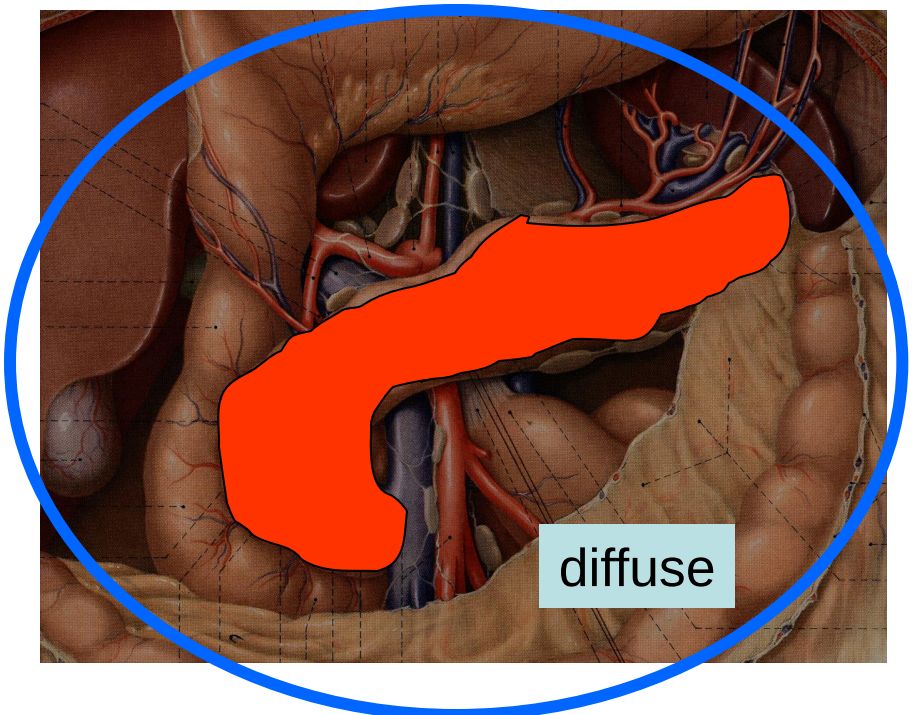

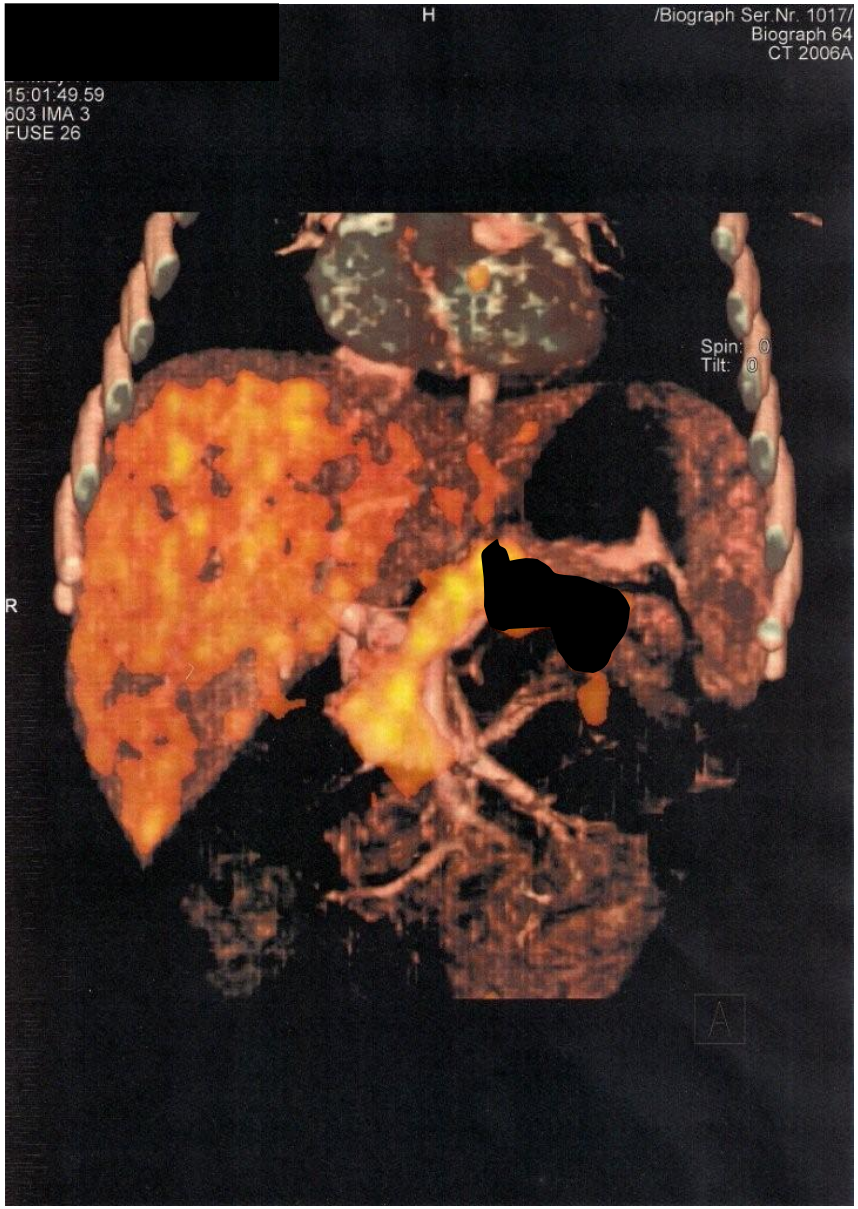


# Yildirim, 21 Monate

- Homozygous KCNJ11
- Octreotide 111μg/kg/d (15-50μg/kg/d)
- Laparoscopic biopsies: diffuse cHI

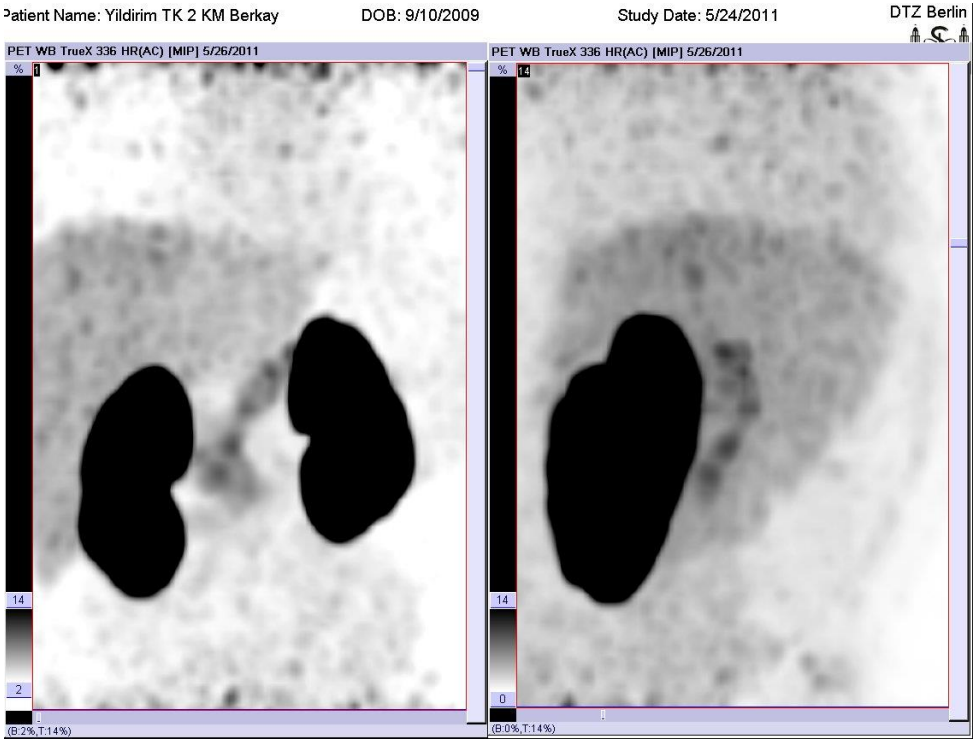

# Restrictive surgery in *diffuse* CHI

| pat | age at diagnosis (months) | mutation | medication before surgery | response to medication | age at surgery (months) | medication after surgery | time follow-up (september 2013) |
|---|---|---|---|---|---|---|---|
| BY | neonatal | KCNJ11 homozygous | octreotide 111 µg/kg/d | insufficient | 21 | none | 29 |
| DI | neonatal | ABCC8 heterozygous dominant | octreotide 90 µg/kg/d | unsatisfactory | 14 | lanreotide 60mg/month | 25 |
| AN | neonatal | none | diazoxide 7.9 mg/kg/d | unsatisfactory | 360 (30 years) | none | 23 |
| EC | neonatal | none | diazoxide 5 mg/kg/d | insufficient | 20 | none | 22 |
| CN | neonatal | none | diazoxide 6.6 mg/kg/d | insufficient | 28 | lanreotide 60mg/month | 22 |
| RP | neonatal | ABCC8 compund heterozygous | diazoxide 8.5 mg/kg/d | insufficient | 7 | lanreotide 60mg/month | 16 |
| SB | neonatal | ABCC8 heterozygous dominant | diazoxide 5mg/kg/d | unsatisfactory | 132 (11 years) | none | 15 |
| AK | neonatal | ABCC8 compound heterozygous | octreotide 20 µg/kg/d + iv glucose 7.6 mg/kg/min | insufficient | 2 | subtotal resection | 8/1 |
| Elizabeth P | neonatal | ABCC8 heterozygous | octreotide 8 µg/kg/d | unsatisfactory | 5 | octreotide 5 µg/kg/d | 8 |
| Elias P | neonatal | ABCC8 heterozygous | octreotide 8 µg/kg/d | unsatisfactory | 5 | none | 8 |

complication n=1 (hematoma)

# Results *diffuse* CHI

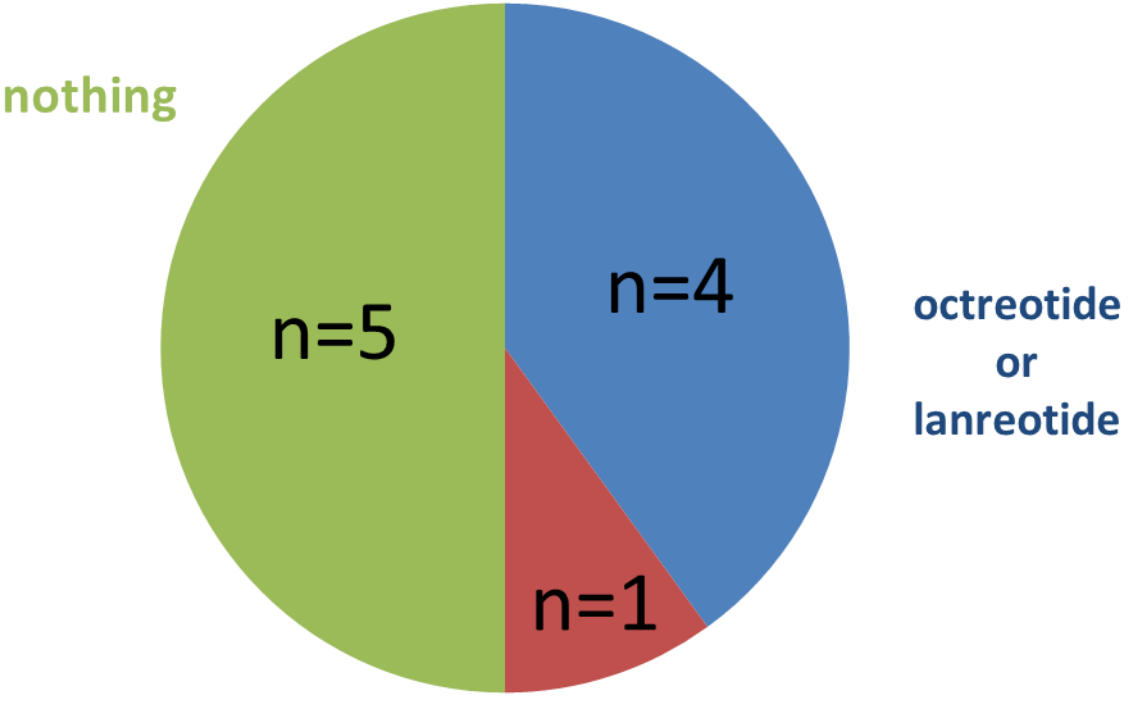


# Dizygotic twins from Argentina

same mutation: ABCC8 p.G716C (c.2146G>T)

same surgery: laparoscopic pancreatic tail resection

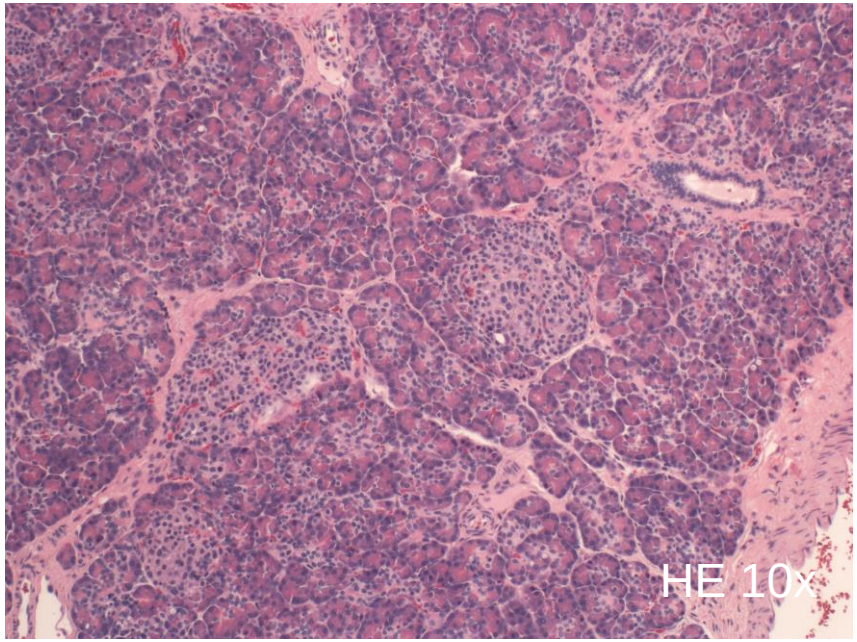


Elizabeth

still on octreotide

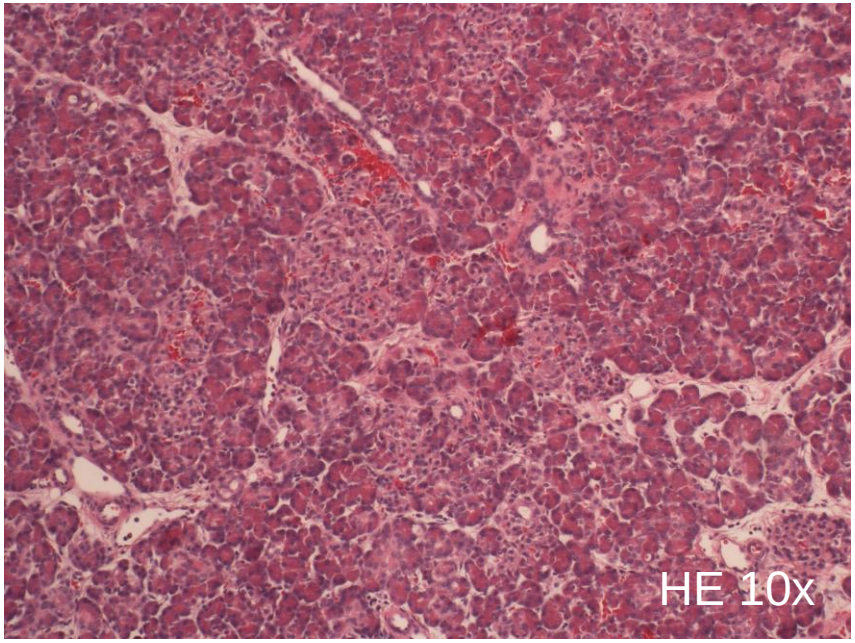


Elias

nothing

## diffuse ≠ diffuse

Pflugers Arch - Eur J Physiol (2011) 462:835–840
DOI 10.1007/s00424-011-1029-z

ION CHANNELS, RECEPTORS AND TRANSPORTERS

# Rapid functional evaluation of beta-cells by extracellular recording of membrane potential oscillations with microelectrode arrays

Thomas Pfeiffer · Udo Kraushaar · Martina Düfer · Sven Schönecker · Dirk Haspel · Elke Günther · Gisela Drews · Peter Krippeit-Drews

**Pharmacology Tübingen, Germany**

pancreas slice of child Eloise from Guatemala




200 µm

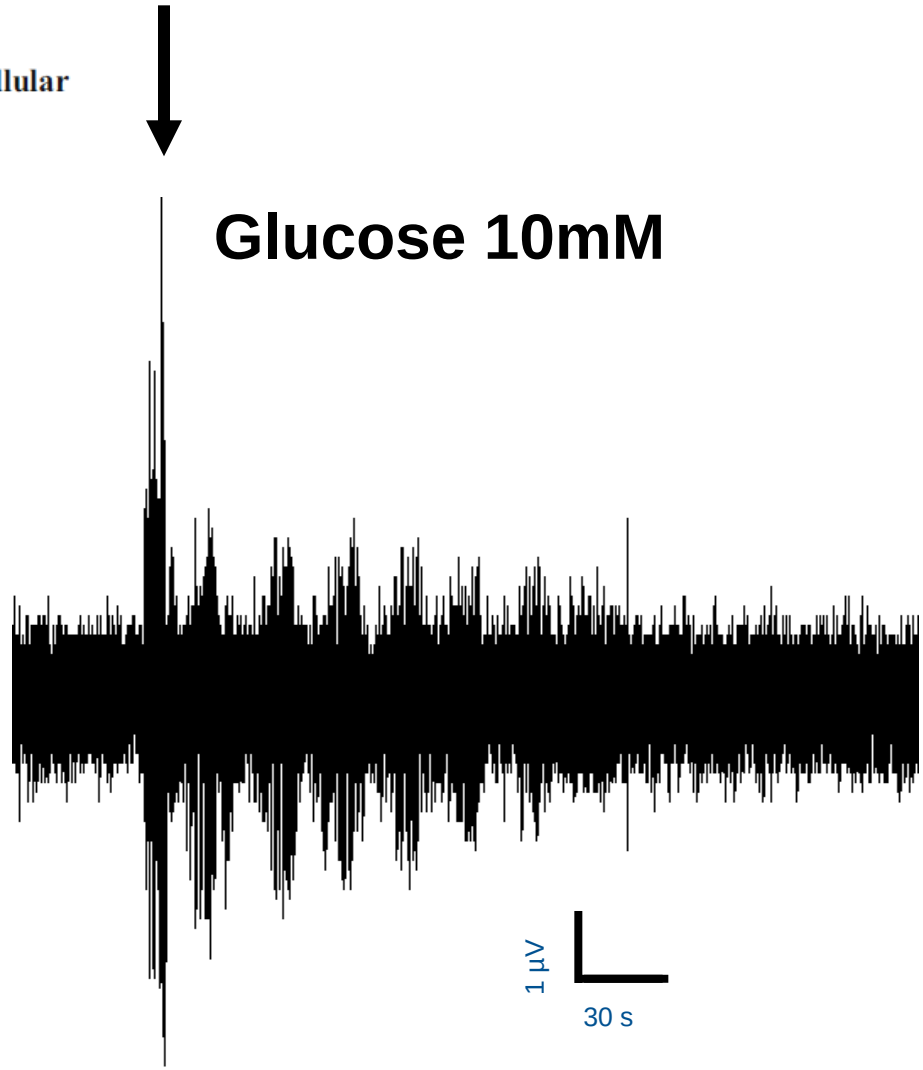


Fraction of plateau phase (FOPP)
= percentage of time with spike activity = 48%

$K_{ATP}$ channel modulators

isolated islet
of Eloise

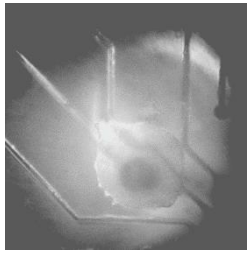

**diazoxide**
**150 µM**

**tolbutamide**
**400 µM**

**Glucose 10mM**

**electrode**

**with islet**

**without**

**5 µV**

**3 min**

# Surgery in Congenital Hyperinsulinism-less *is* more !

- cure in *focal* CHI: 95%
- weaning of medication in *non-focal* CHI : 43%
- reducing the risk of diabetes

Hyperinsulinism
Germany · International

## Greifswald





## Magdeburg

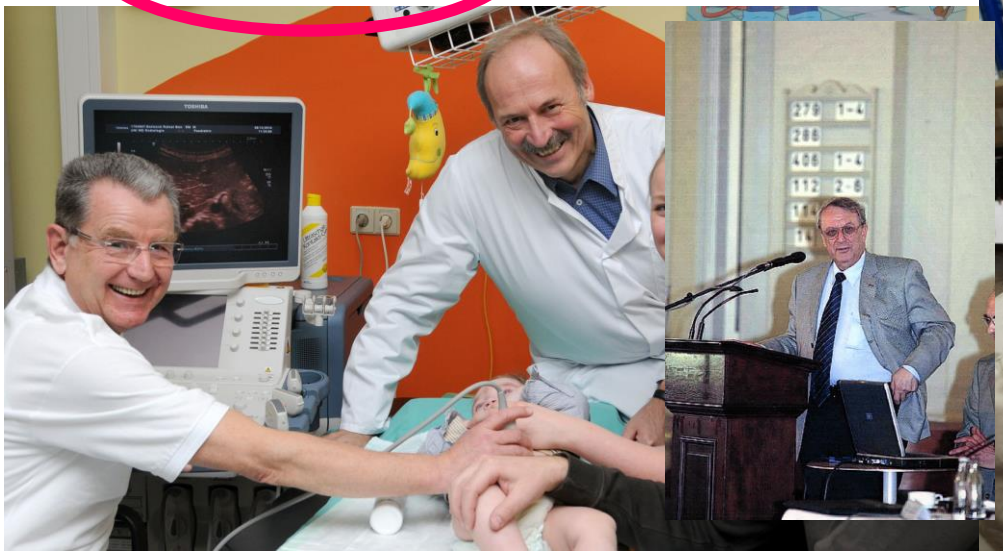


## Berlin

en

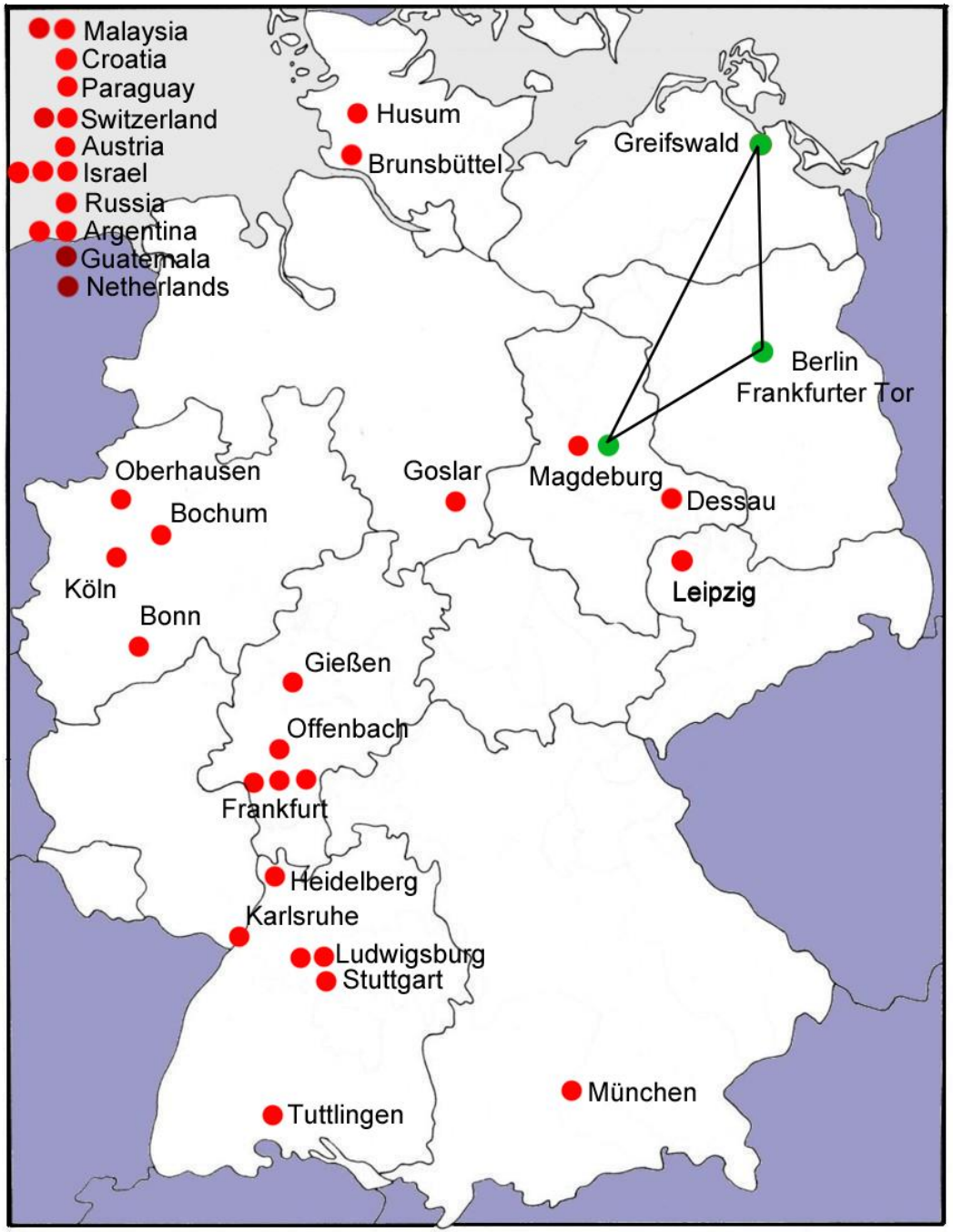


Hyperinsulinism
Germany · International

referral area for CHI surgery
n=34
since 2010

from abroad 44%

# Greetings from Germany !

CHI
Congenital
Hyperinsulinism
International

**5th Congenital Hyperinsulinism Family Conference**
**September 17-18, 2013**
**NH Milano 2 Hotel**
**Segrate, Italy**

**Tuesday, September 17, 2013**