Lina, * 2008

2860 g, GA 38 weeks

At age 84 hour seizure
Blood glucose 1.2 mmol/l (=22 mg%)
Metabolic test regular (NH4, FFS, ßOHB, Cortisol, org. acids)

Glucose response glucagon

diazoxide (15 mg/kg) → resistent

[18F]F-DOPA PET was done at home hospital: diffuse pattern

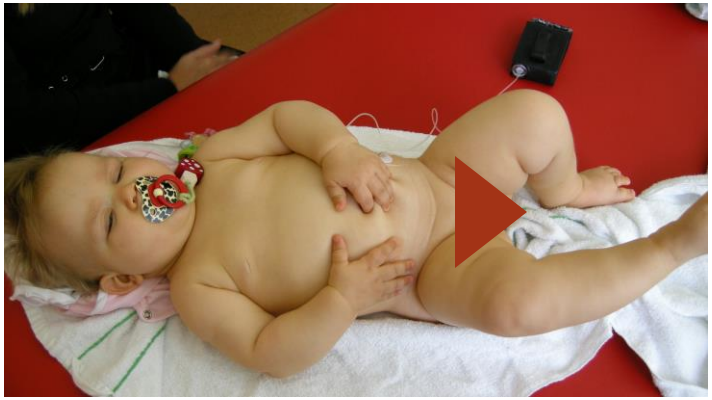

Lina, * 2008

euglycaemia with octreotide 20µg/kg*day s.c. pump

No further diagnosis until 7/2009

→ referred to Magdeburg

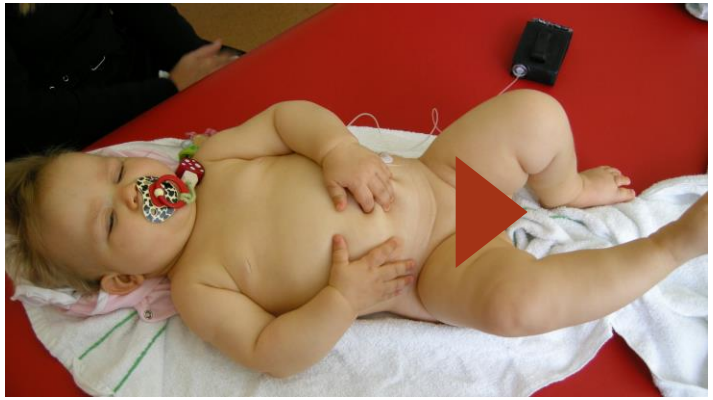

www.hyperinsulinismus-hilfe.de

Lina, * 2008

Mutational analysis: at age 13 months

ABCC8-mutation in child and father
c.2117 – 2A>T, mother neg.

L-Dopa-PET/CT at `Frankfurter Tor:
focal lesion in pancreatic tail

Laparoscopic focus resection (2 cm)
(W. Barthlen, Greifswald)

stabile euglycaemia

OTTO VON GUERICKE UNIVERSITÄT MAGDEBURG MED MEDIZINISCHE FAKULTÄT

[18F]F-DOPA-PET/CT in DTZ

`Frankfurter Tor´(W. Mohnike)

focal Form

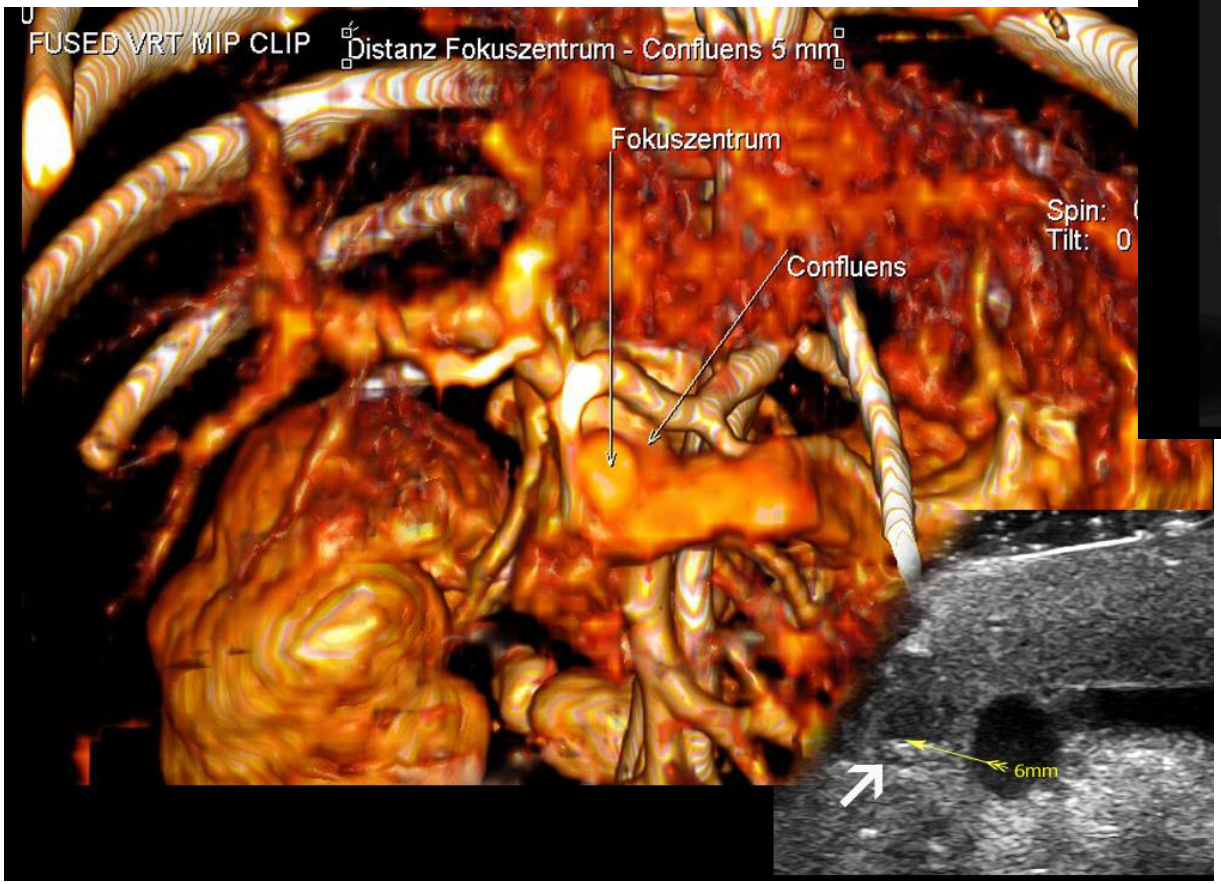

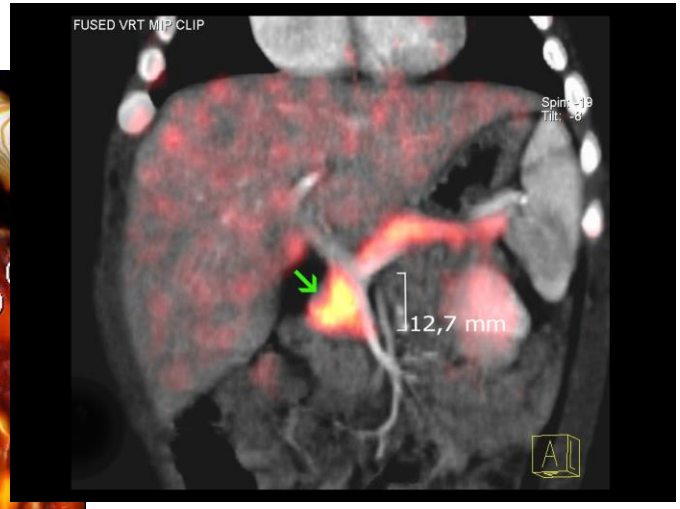

L. v Rohden:
intraoperative ultrasound

[18F]F-DOPA-PET/CT in DTZ `Frankfurter Tor´(W. Mohnike)

focal type

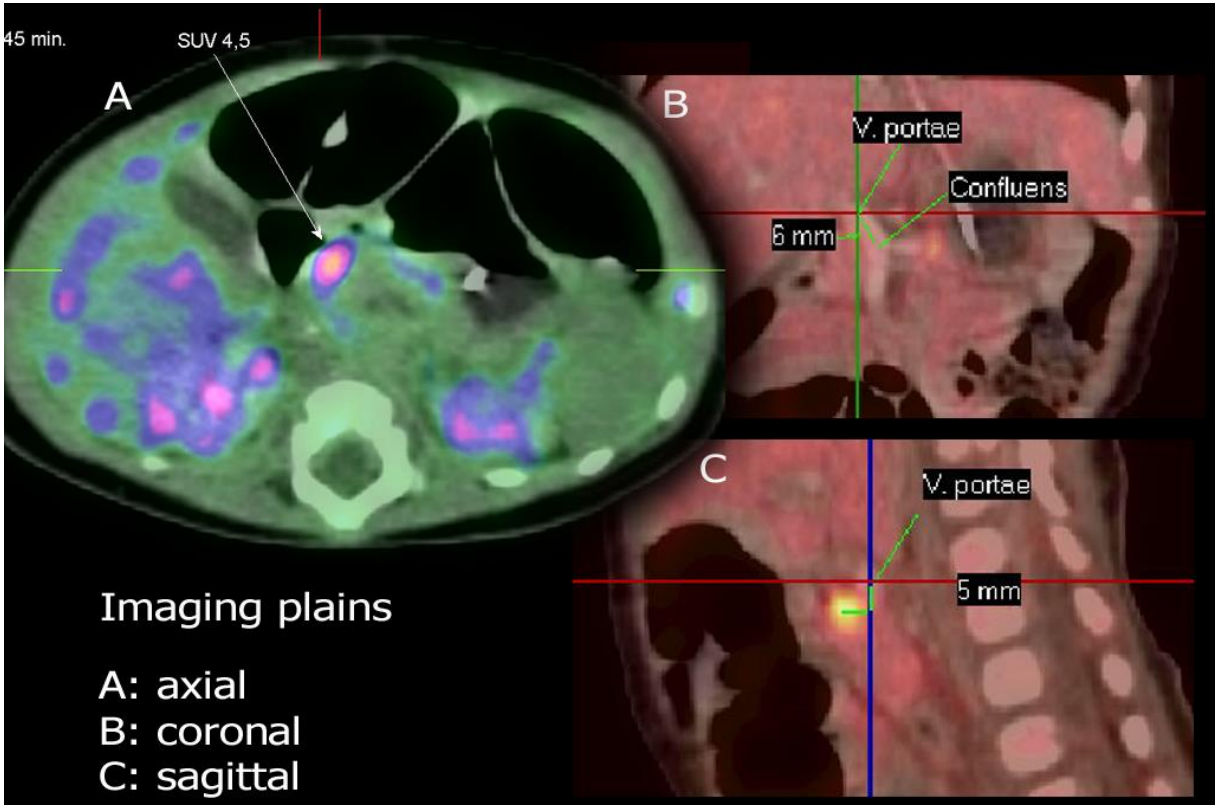

OTTO VON GUERICKE UNIVERSITÄT MAGDEBURG MED MEDIZINISCHE FAKULTÄT

[18F]F-DOPA-PET/CT in DTZ

`Frankfurter Tor´(W. Mohnike)

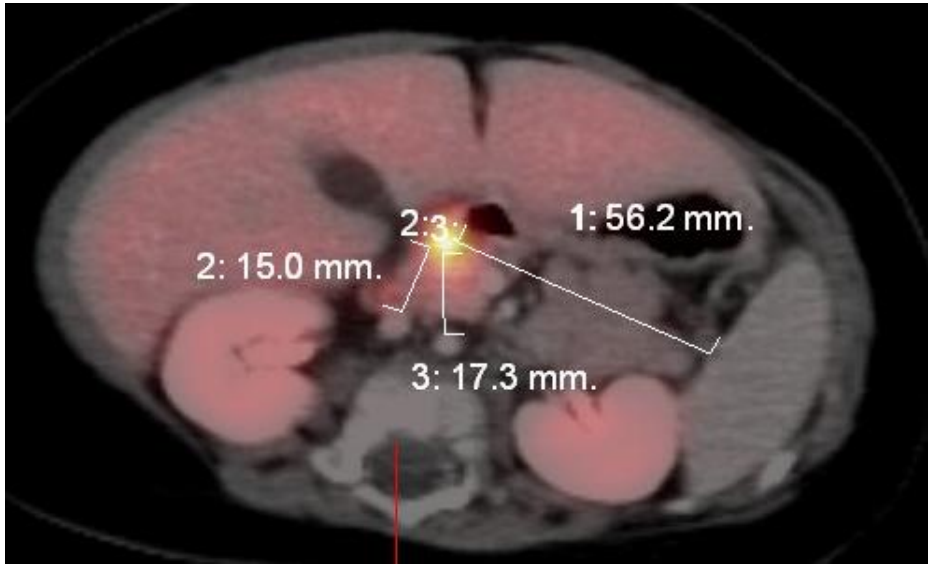

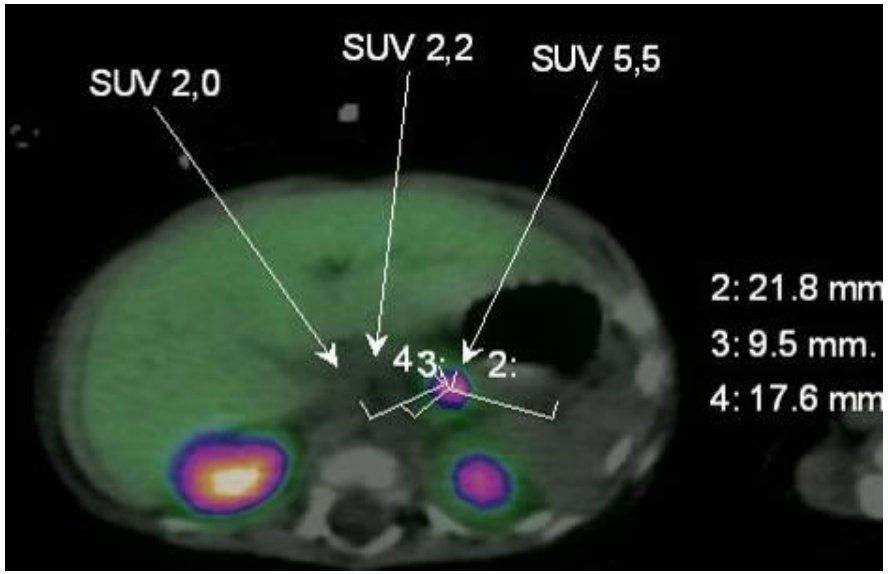

Localisation by F18-Fluoro-L-DOPA PET-CT

Problems:

- [18F]F-DOPA emerged in single scans are difficult to interpret
- Gallbladder, pancreatic head/ uncinatus
- Higher specificity has been experienced by repeated images in case of focal uptake
- Accuracy of localization has been increased by image recalculation

OTTO VON GUERICKE UNIVERSITÄT MAGDEBURG MED MEDIZINISCHE FAKULTÄT

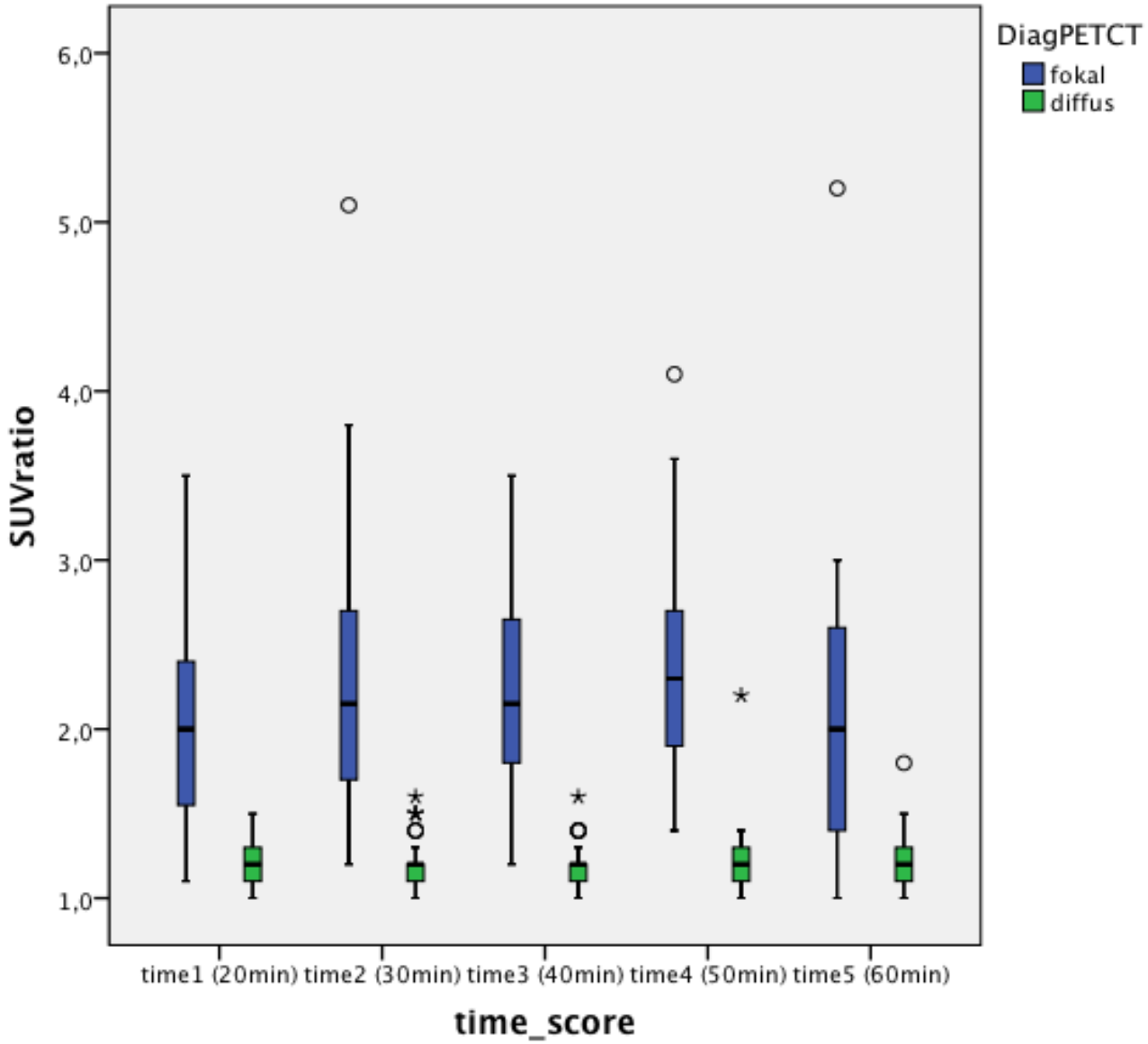

special pattern in focal forms

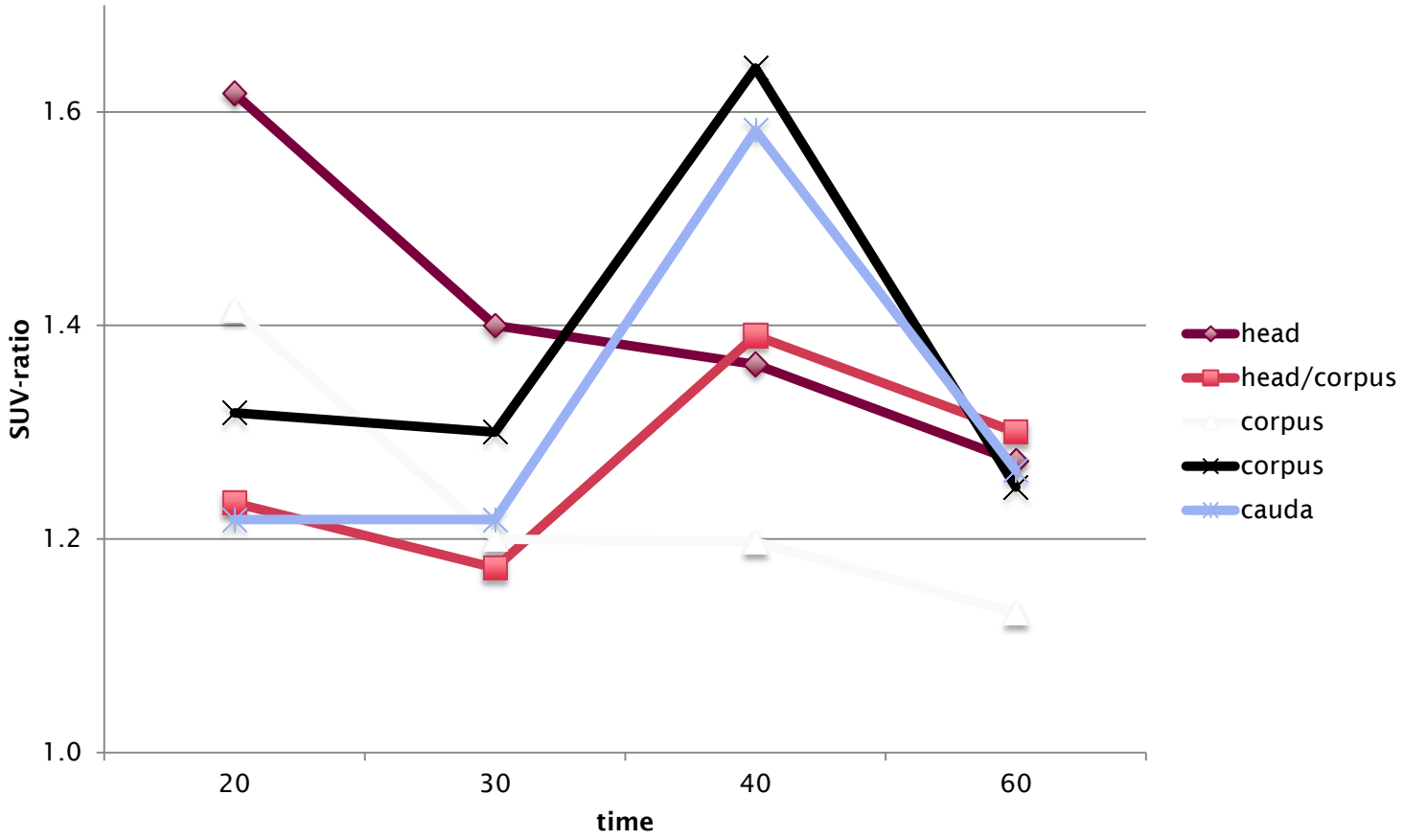

accuracy

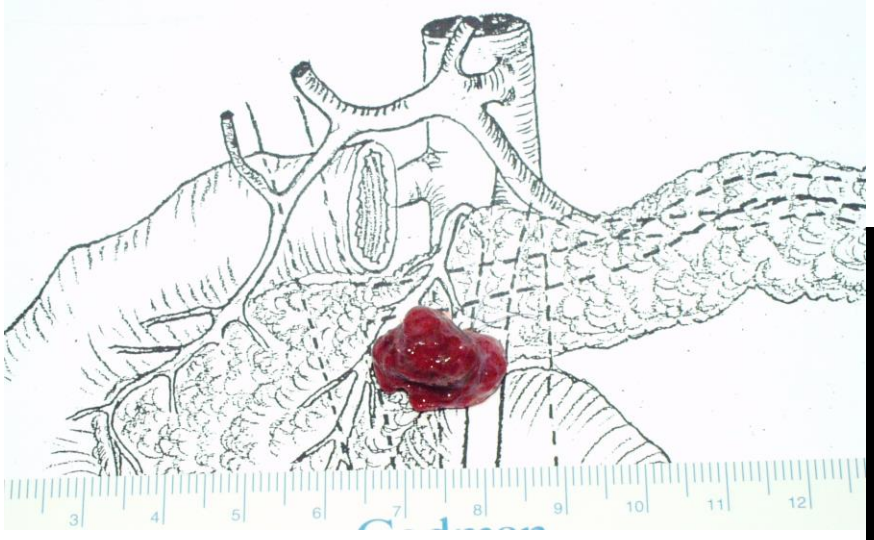

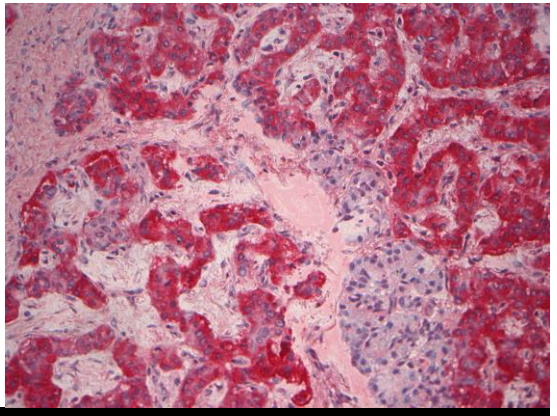

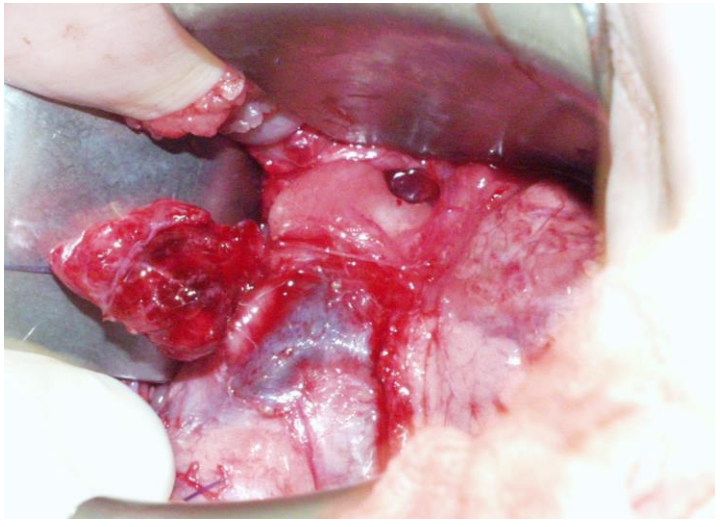

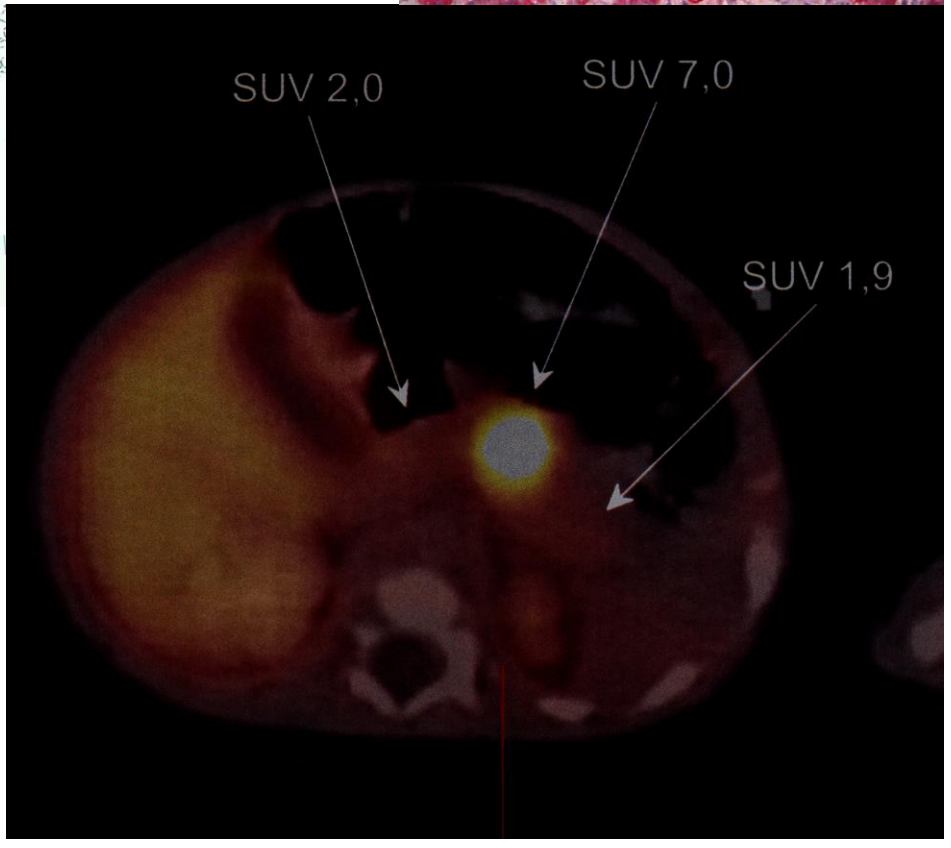

Intraoperative ultrasound

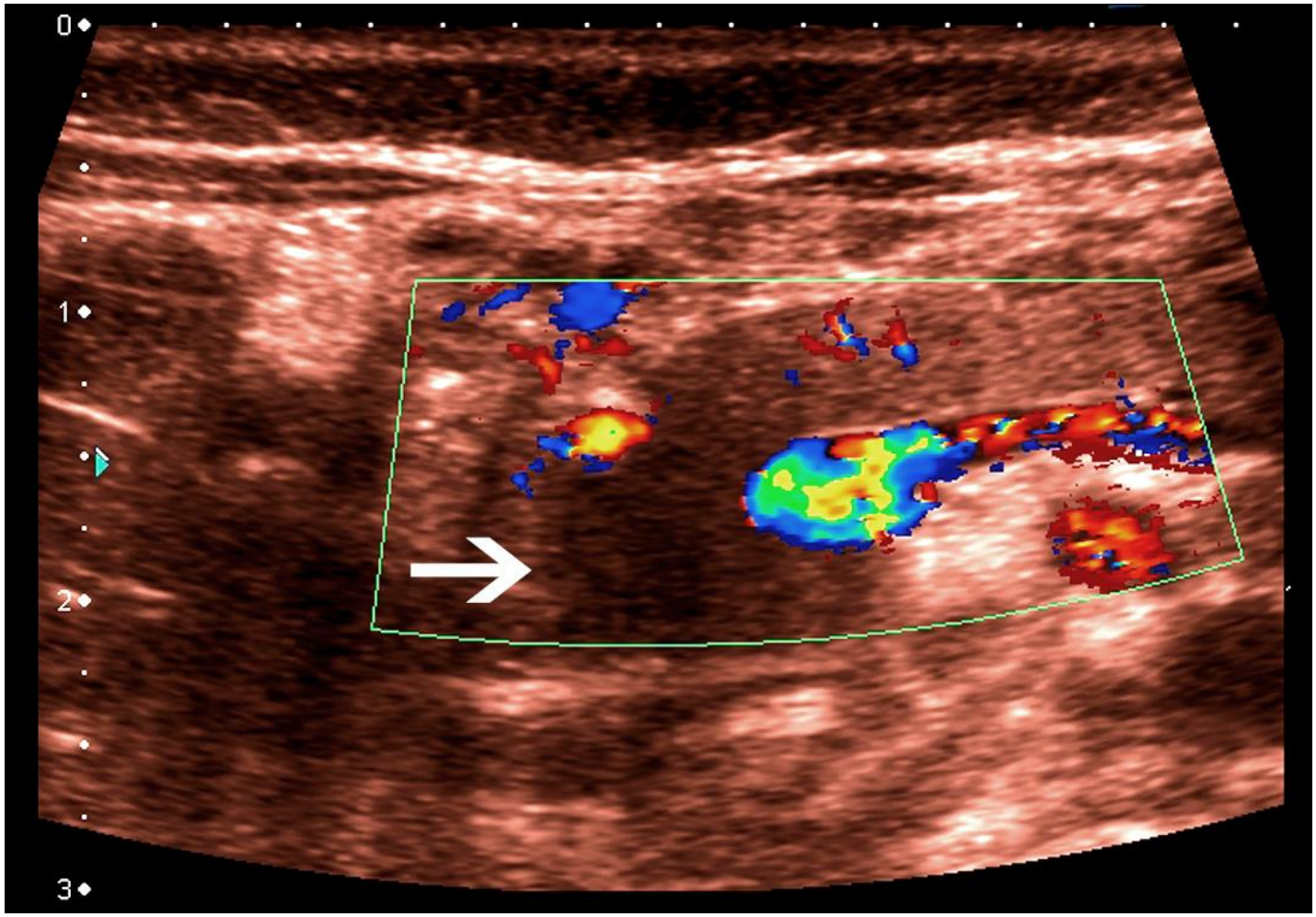

[18F]F-DOPA-PET/CT in DTZ `Frankfurter Tor´(W. Mohnike)

- ✓ Between 2004 and 2013, a [18F]F-DOPA-PET/CT was performed in 138 patients (58 girls) (median age: 0.53y; range: 0.09-30.35y.).
- ✓ Mutation analysis of ABCC8 and KCNJ11 were carried out in the index patient and their parents.
- ✓ Pancreatic surgery was done in 43%

OTTO VON GUERICKE UNIVERSITÄT MAGDEBURG MED MEDIZINISCHE FAKULTÄT

[18F]F-DOPA-PET/CT in DTZ

`Frankfurter Tor´(W. Mohnike)

focal uptake of [18F]F-DOPA in 33 %

localization of the lesion

Head:	31 %,	head/corpus:	9 %
Corpus:	24 %,	corpus/cauda:	4 %
Cauda:	31 %		

[18F]F-DOPA-PET/CT in DTZ

`Frankfurter Tor´(W. Mohnike)

Surgery

- ✓ Histology: 93 % focal
- ✓ Mutational analysis:
  - pat. heterozygous
    - ABCC8: 73 %
    - KCNJ11: 11%

Accuracy of localization, acc. to surgeon: 100 %

[18F]F-DOPA-PET/CT in DTZ `Frankfurter Tor´(W. Mohnike)

Surgery in patients with diffuse uptake of [18F]F-DOPA: 18 %

- ✓ Histology: 94 % diffuse
- ✓ Mutational analysis:
  - ✓ heterozygous mutation in ABCC8: 41 %
  - ✓ comp. heteroz./ homozygous in ABCC8/ KCNJ11: 18 %

OTTO VON GUERICKE UNIVERSITÄT MAGDEBURG MED MEDIZINISCHE FAKULTÄT

[18F]F-DOPA-PET/CT in DTZ

`Frankfurter Tor´(W. Mohnike)

Surgery in
focal uptake of [18F]F-DOPA: 33 %
diffuse uptake: 12 %

out of all surgery:
sensitivity of focal: 100 %
specificity: 85 %.

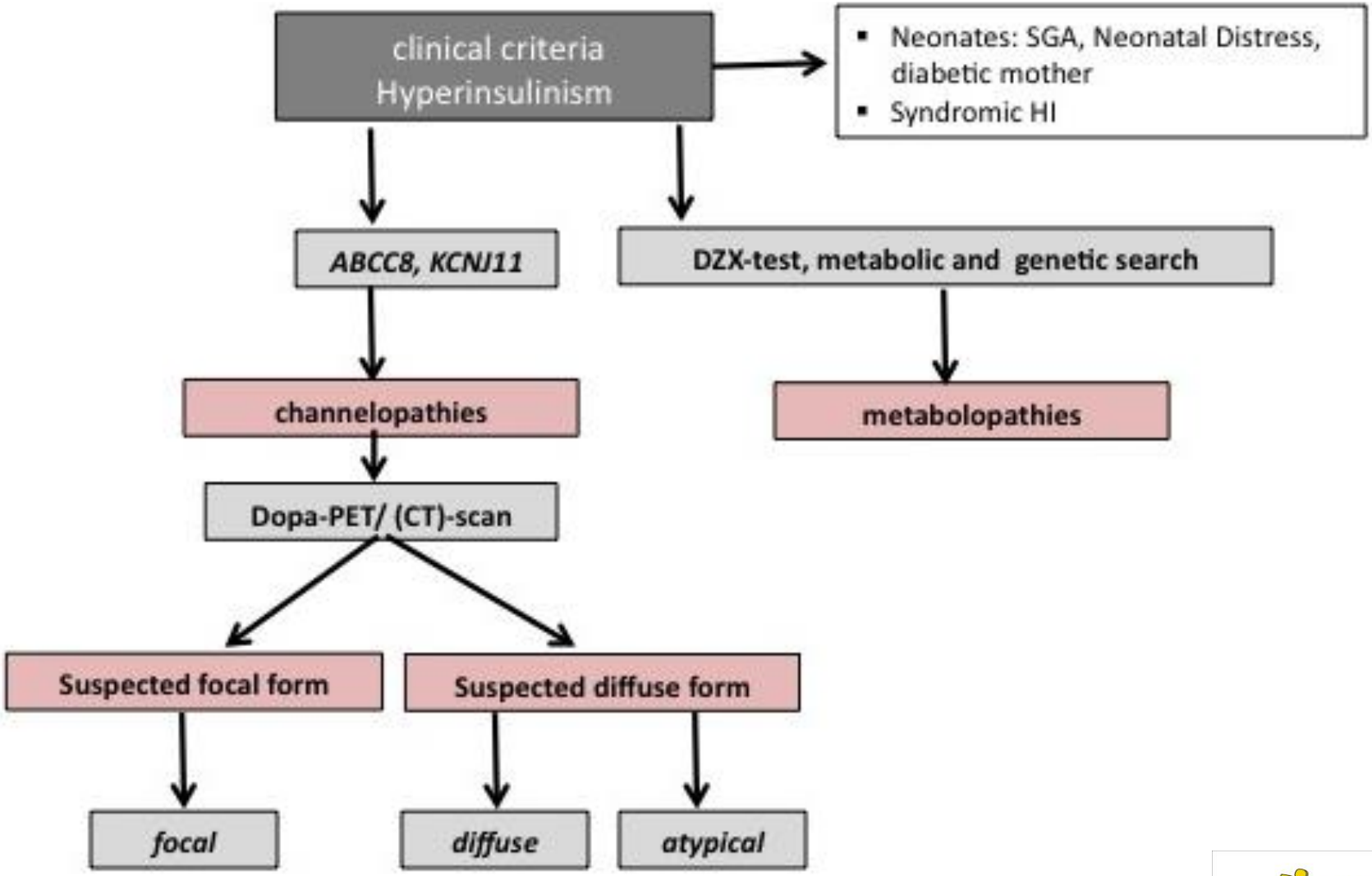
clinical criteria
Hyperinsulinism
Neonates: SGA, Neonatal Distress, diabetic mother
Syndromic HI
ABCC8, KCNJ11
DZX-test, metabolic and genetic search
channelopathies
metabolopathies
Dopa-PET/ (CT)-scan
Suspected focal form
Suspected diffuse form
focal
diffuse
atypical


Many thanks!

Histologie

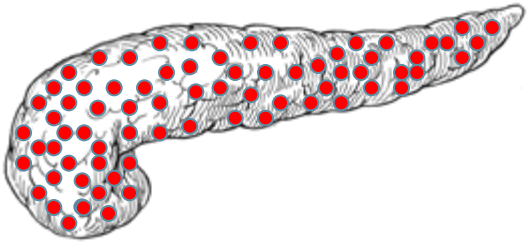

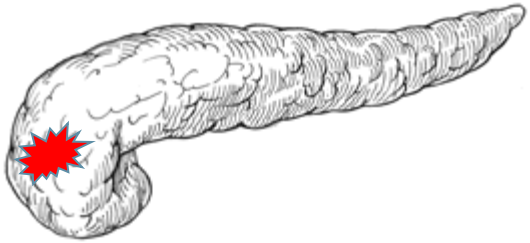

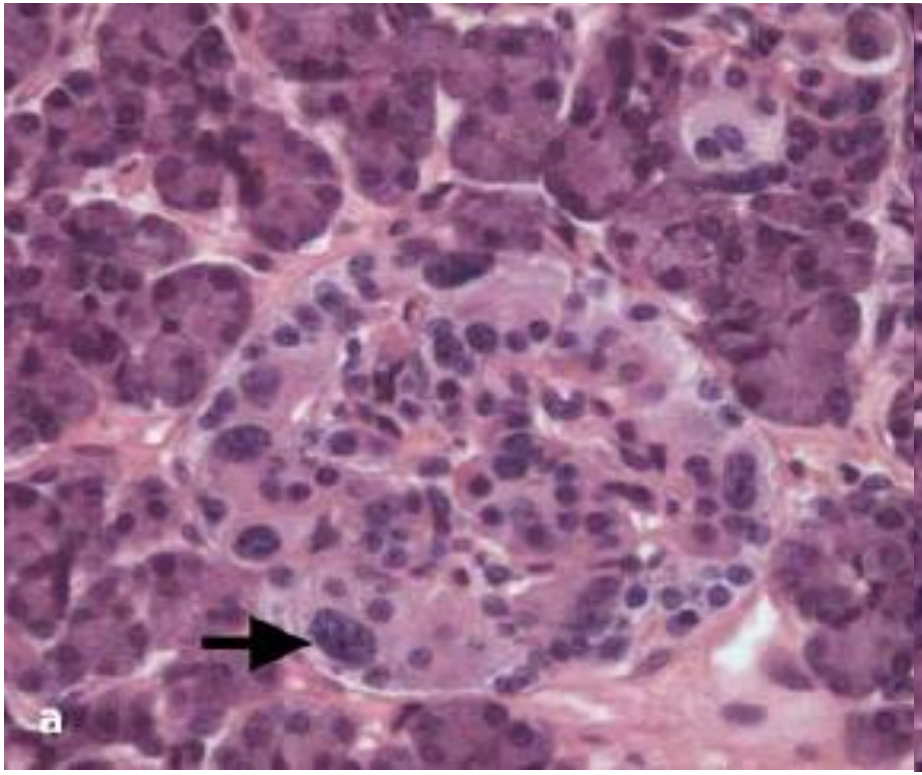

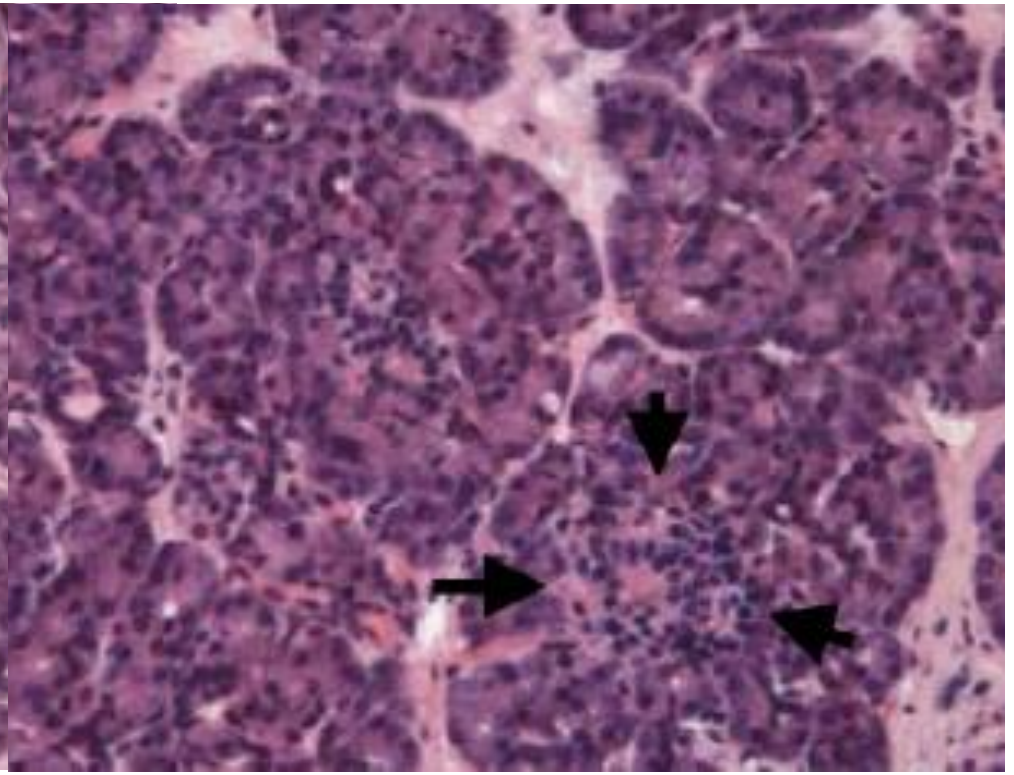

Genetik der K_{ATP}-Kanalerkrankungen

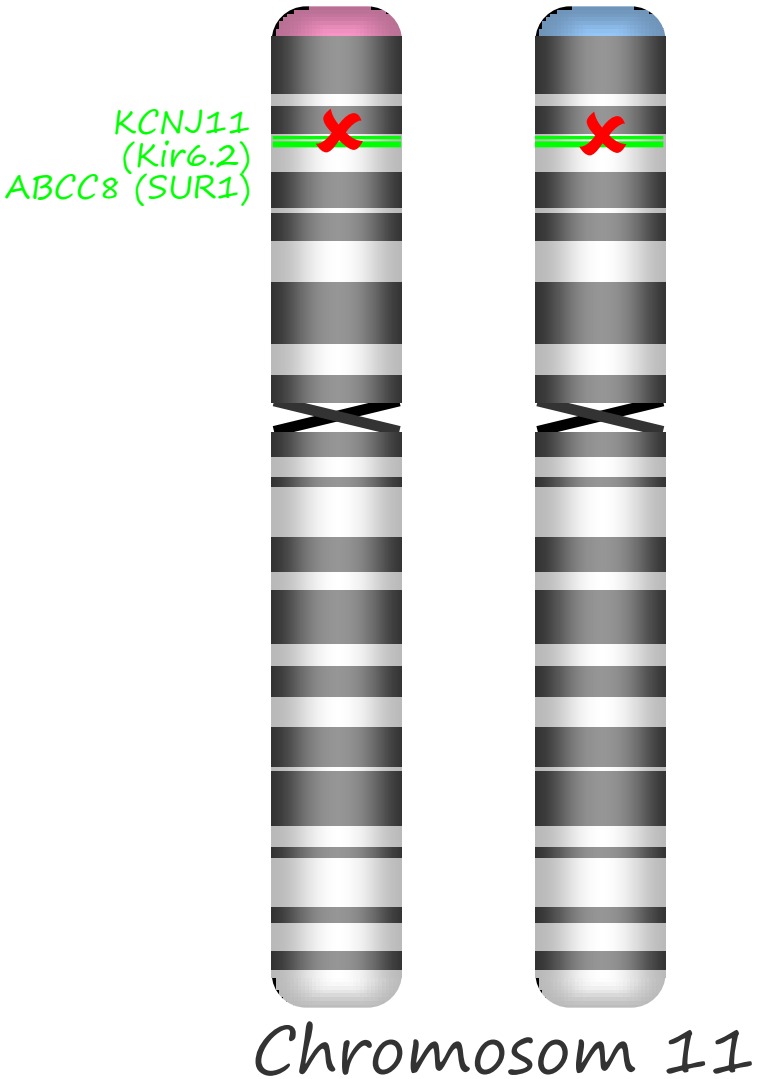

Autosomal-rezessiv

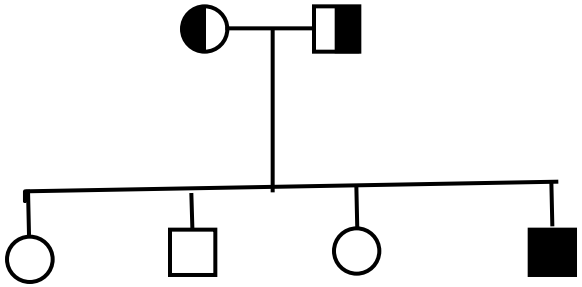

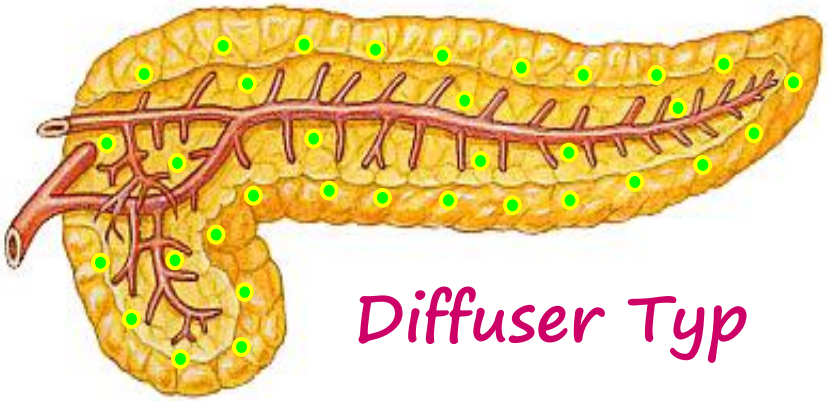

Genetik der K_{ATP}-Kanalerkrankungen

Heterozygote, paternal vererbte, rezessive Mutation

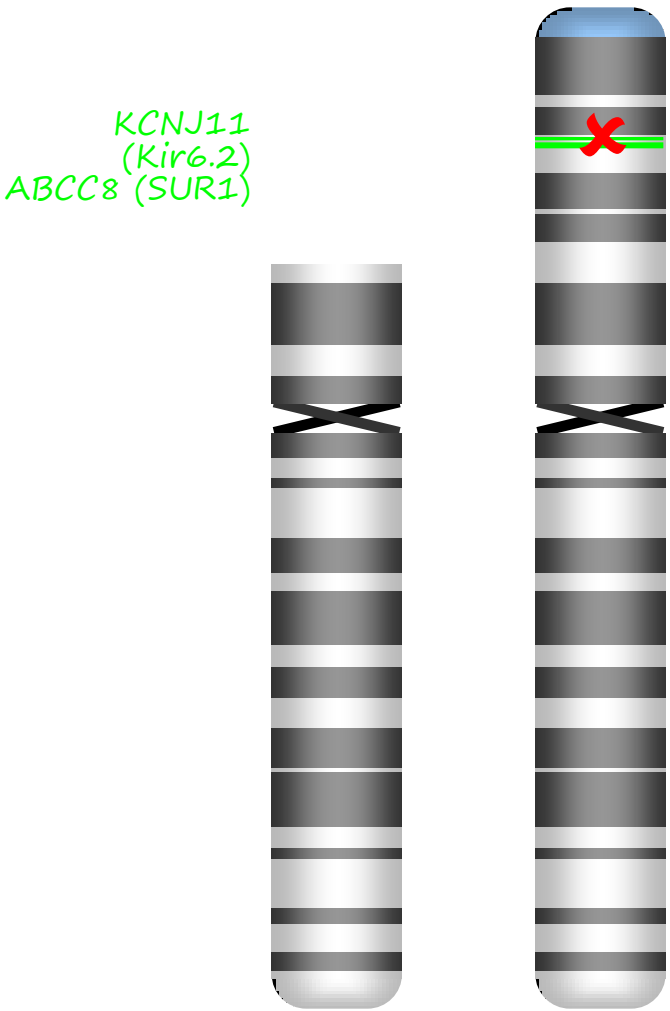

Chromosom 11

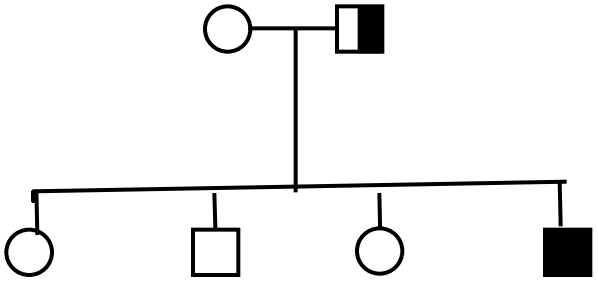

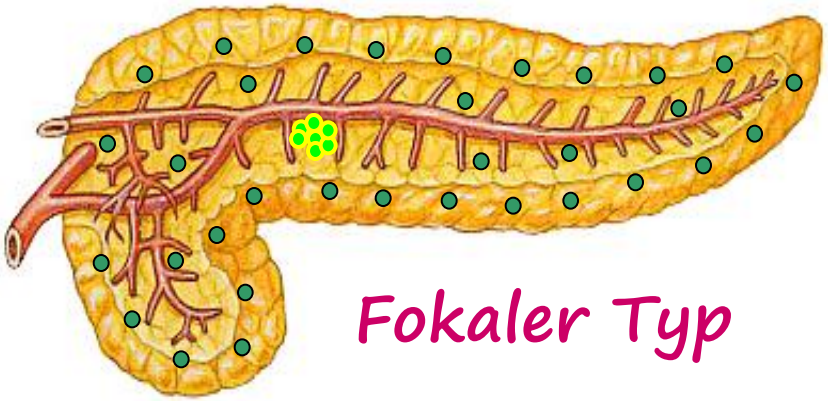

„Second-Hit in Inselzelle bei paternal vererbter Mutation: 1:270

Genetik der K_{ATP}-Kanalerkrankungen

Heterozygote, paternal vererbte, rezessive Mutation

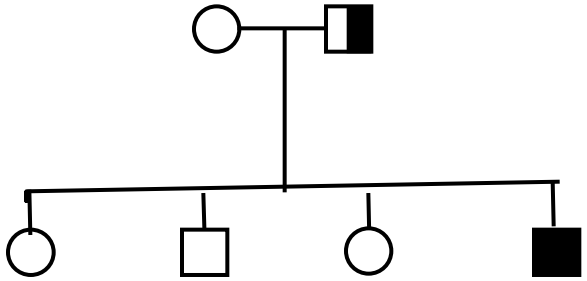

	KCNJ11	*ABCC8*
DNA Blut	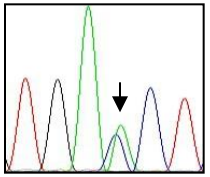	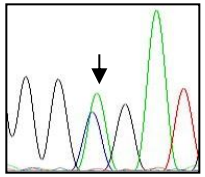
DNA Pankreas normal	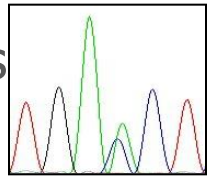	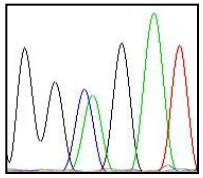
DNA Pankreas Fokus	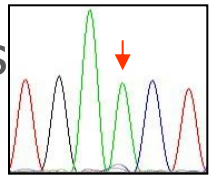	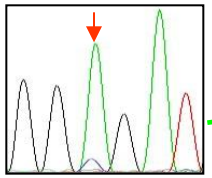
	Mutation c.612C>A p.D204E	*SNP rs75710 (Exon 33)*

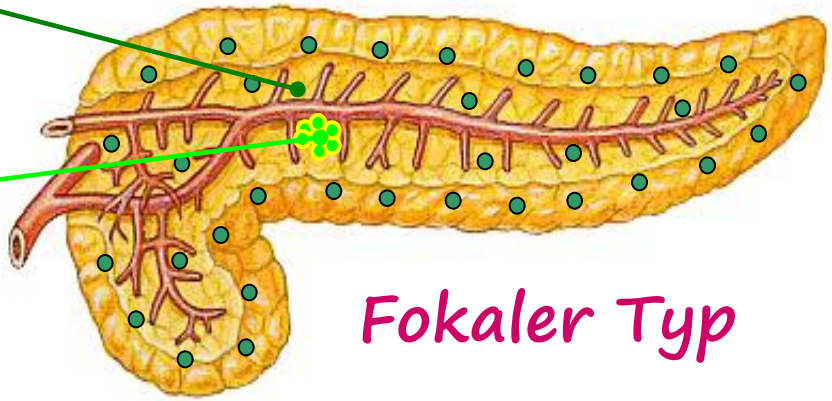

Fokaler Typ

I.Wieland, Magdeburg; S. Vogelgesang, Greifswald

F18-Fluoro-L-DOPA PET-CT

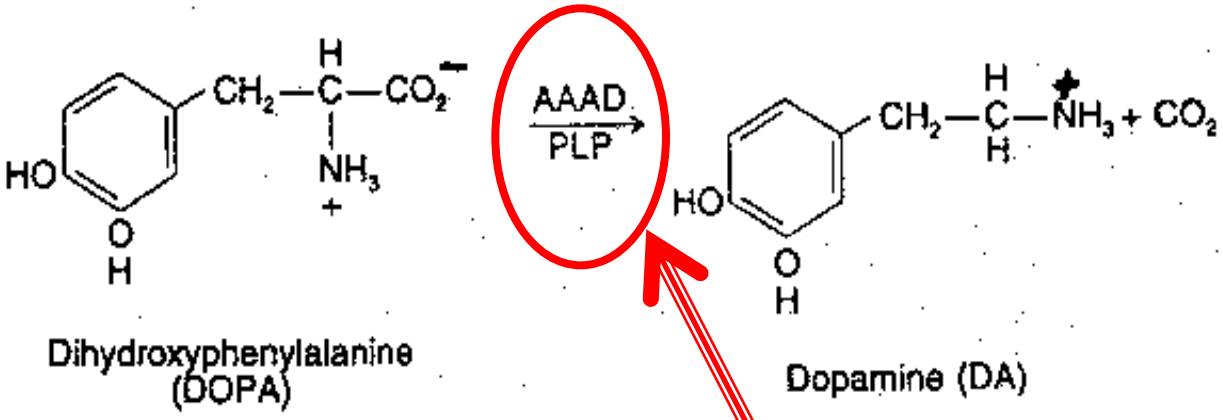

Dopamindecarboxylase

1. Pankreaszellen nehmen DOPA auf.
2. Dopamin ist Transmitter in neuroendokrinen Geweben,
3. Konversion in Dopamin ist von der aromatischen Aminosäuredecarboxylase abhängig.

Zusammenfassung

1. Klinisches, genetisches, morphologische heterogenes Krankheitsbild
2. keine Differenzierung nach,
   - Geburtsgewicht
   - Glukosebedarf,
   - Glukose / Insulin,
   - Glukagonresponse

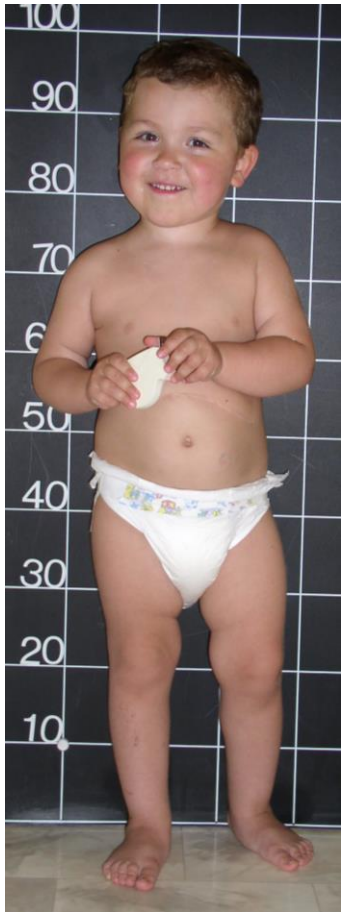

Zusammenfassung

3.Genetisch kann in 50% der Fälle kein ursächlicher Defekt nachgewiesen werden

4.1/3 Patienten haben einen umschriebenen Fokus,

5.Charakteristisch ist paternale Mutation in ABCC8 oder KCNJ11

6.in Cauda oder Corpus laparoskopische OP