



Surgical Management of Hyperinsulinism

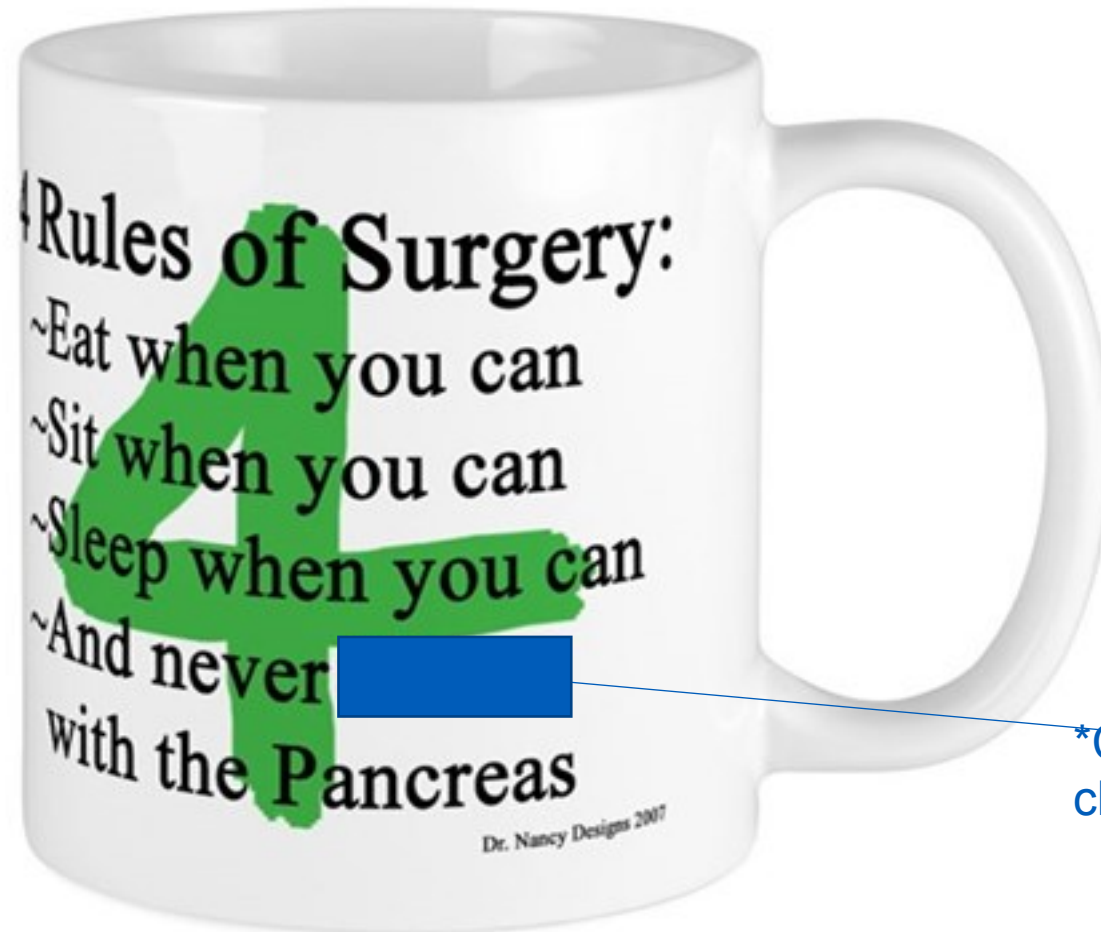
Chip Uffman, MD MPH
Cook Children's Medical Center
Fort Worth, TX
June 1, 2024



Disclosures

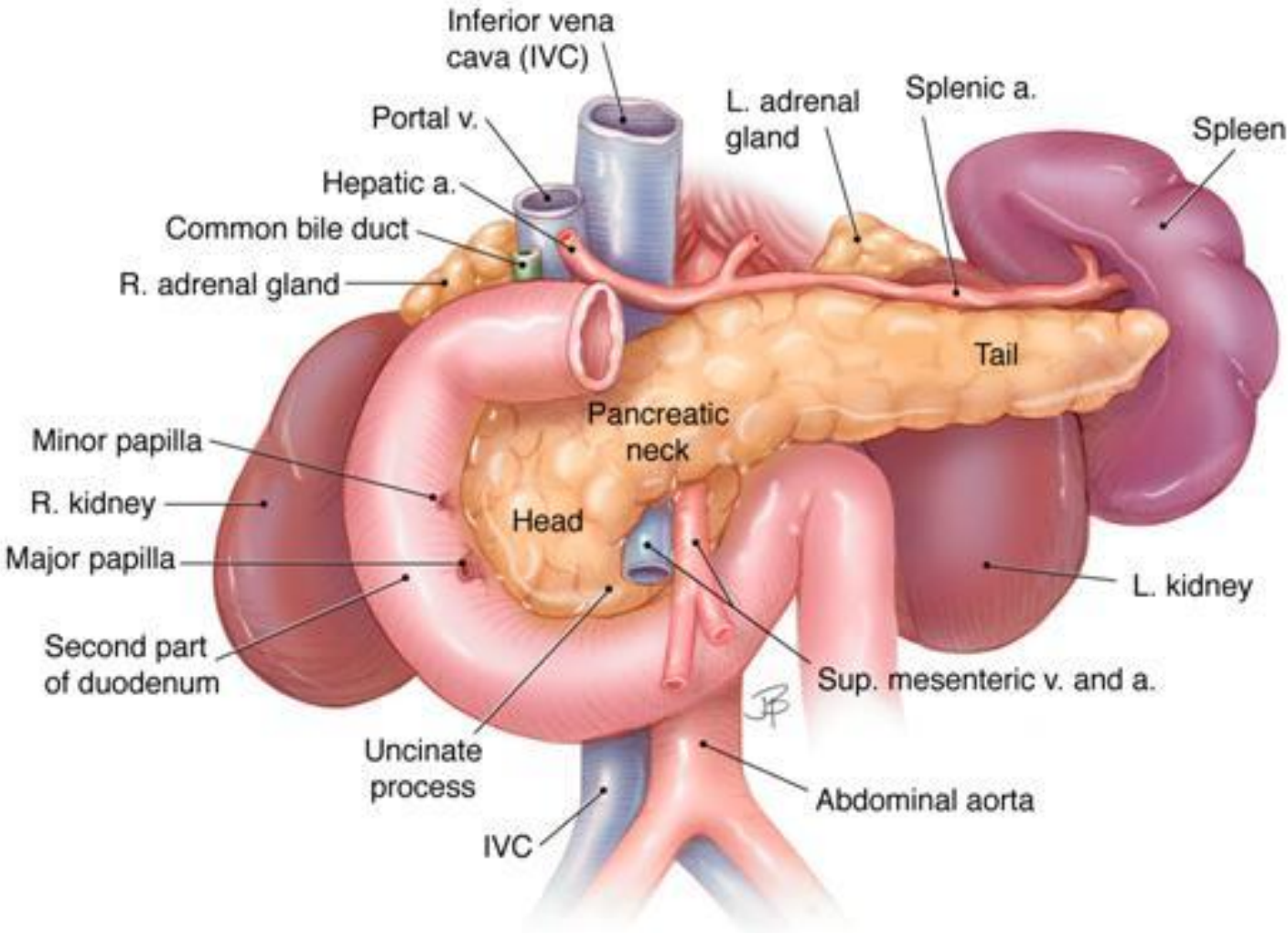
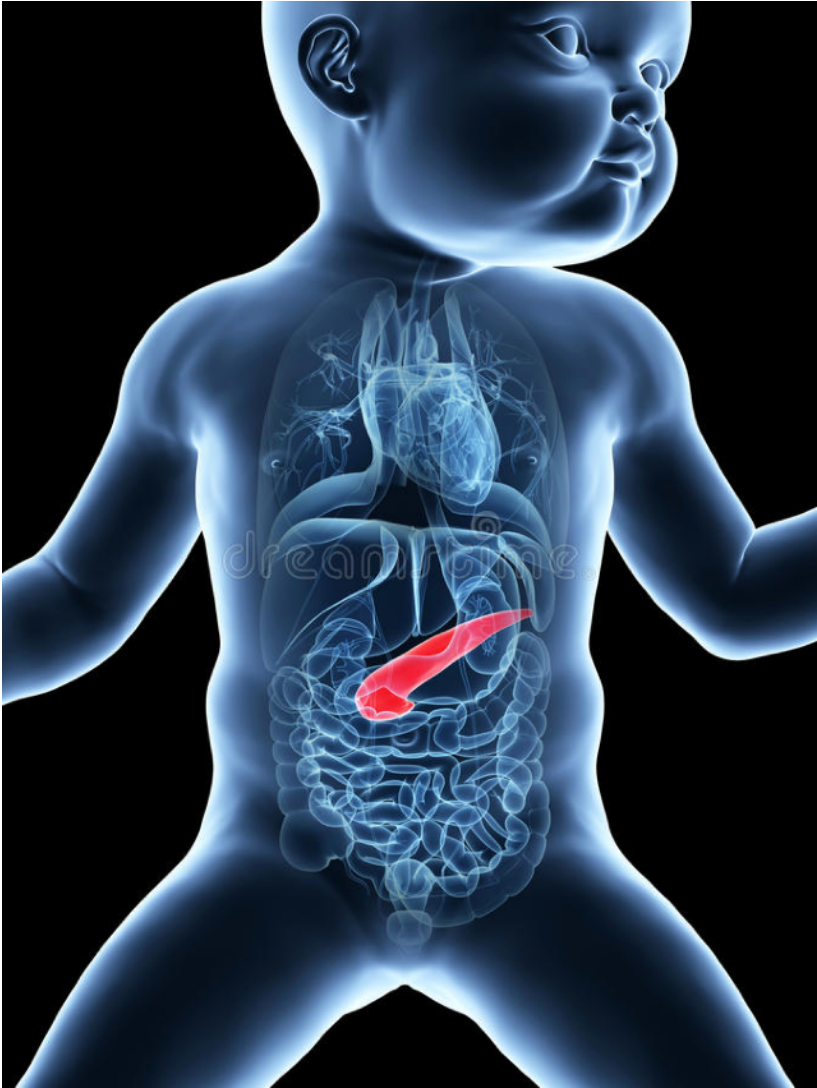


Pediatric Surgery Training

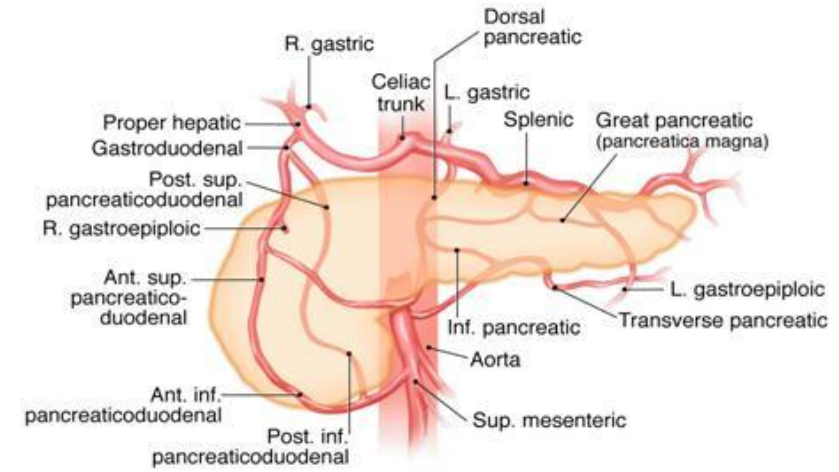
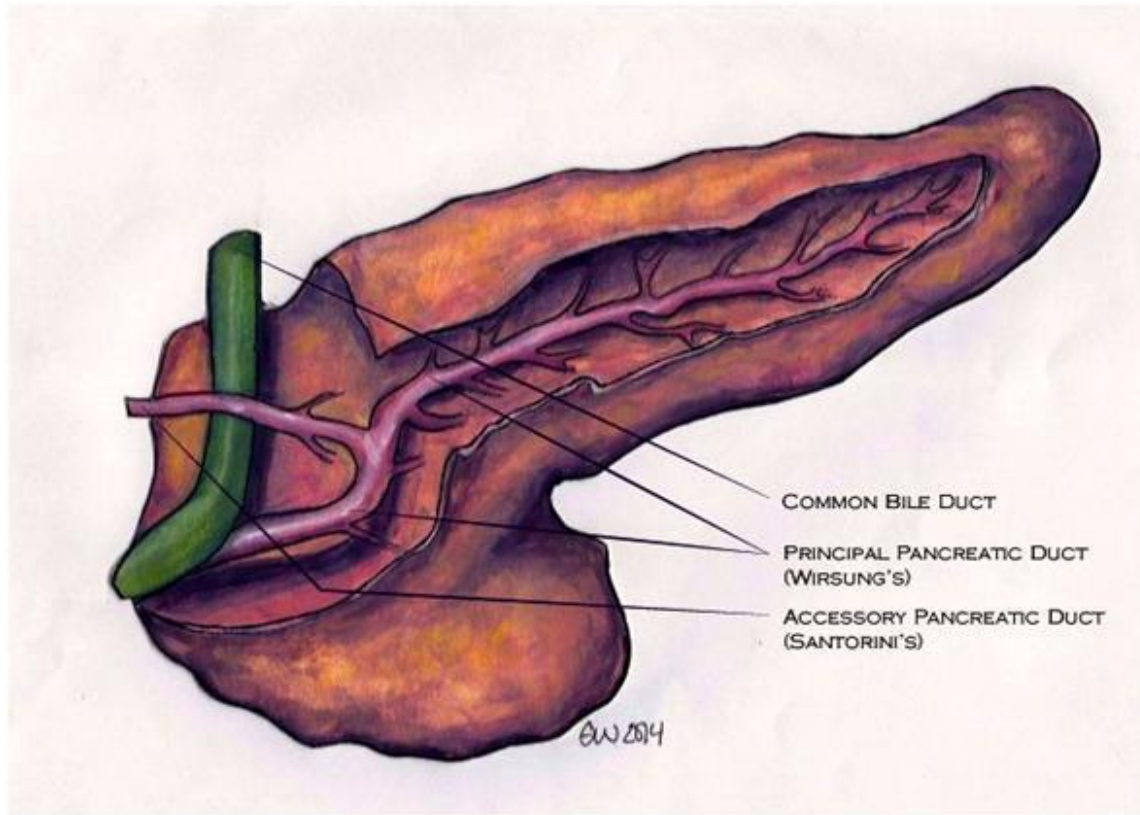


Censored by most children's hospitals

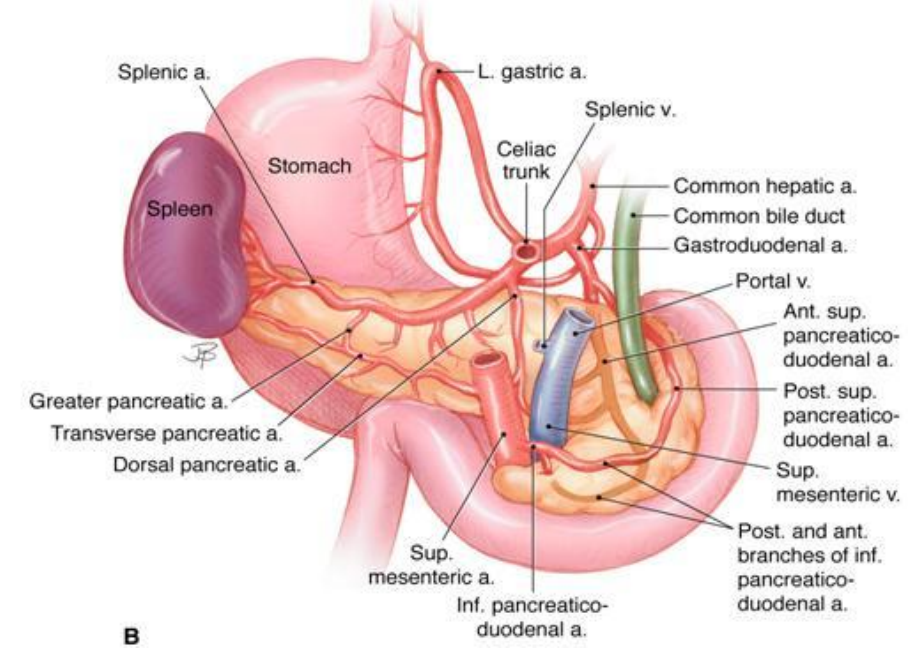
Pancreatic Anatomy



Anatomy



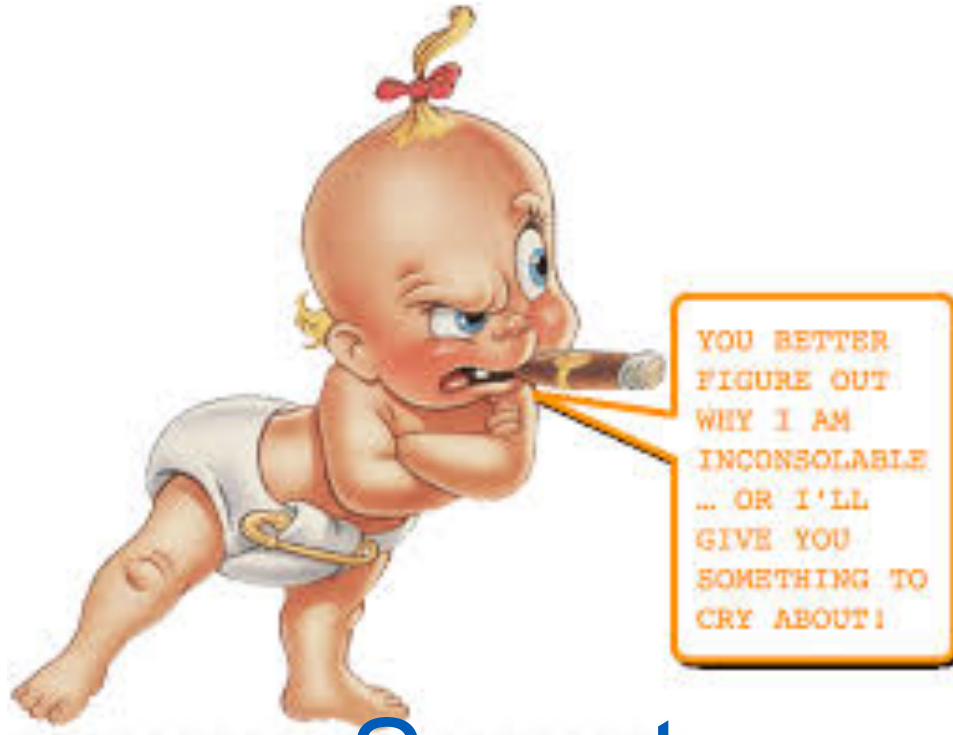
A



B

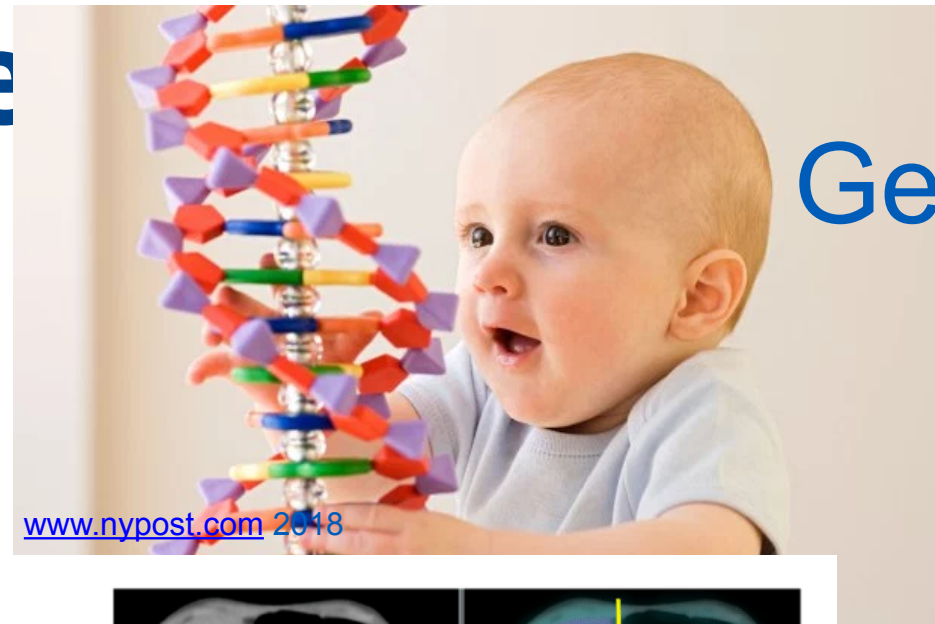
Decision for Surgery

Genetics



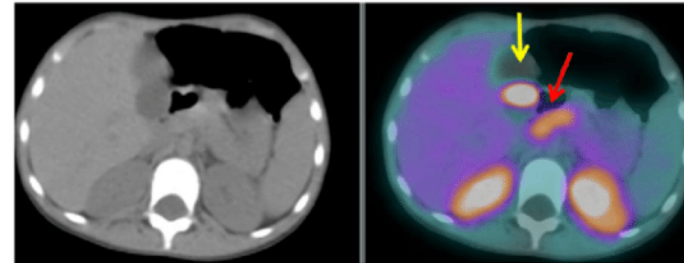
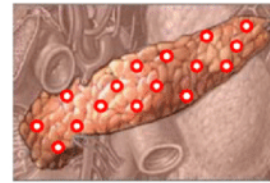Symptoms

www.PediatricEMMorsels.com 2018



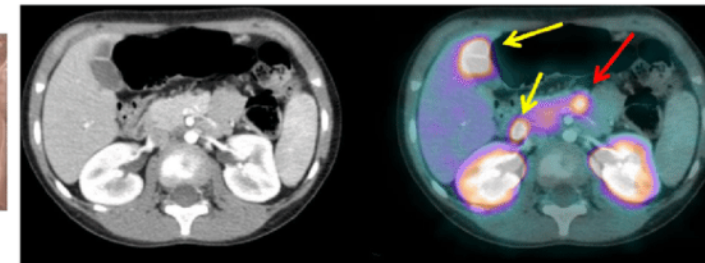
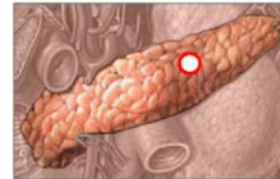www.nypost.com 2018

Diffuse form



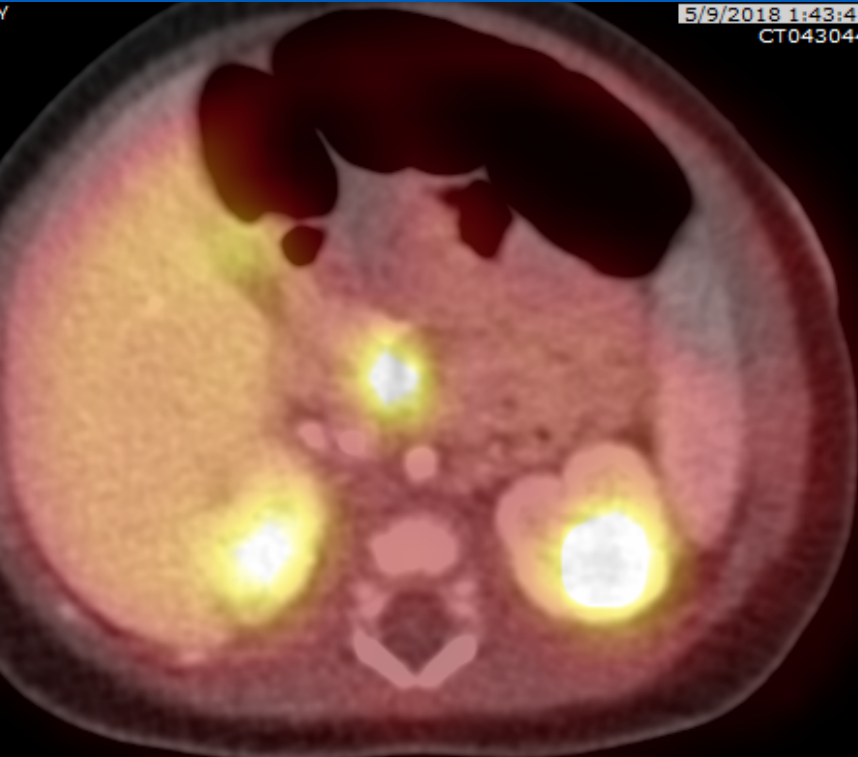
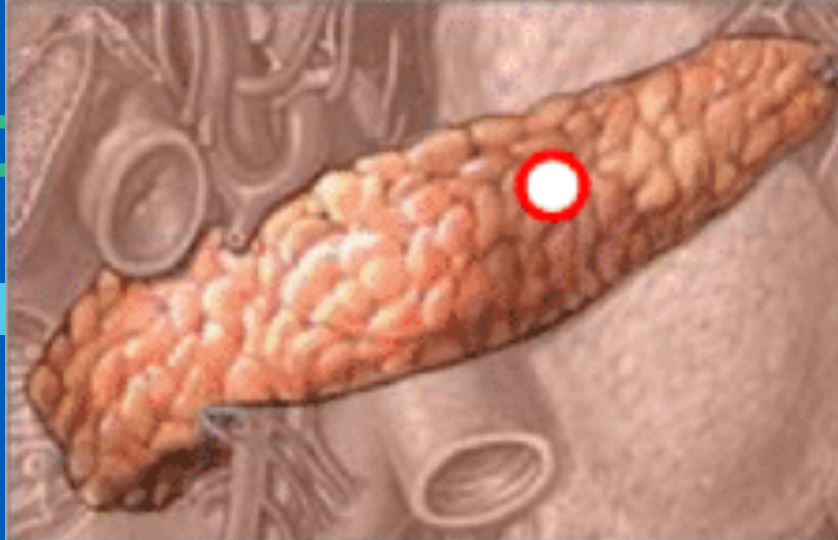www.researchgate.net 2018

Focal form



Imaging

PET Scan- Foc

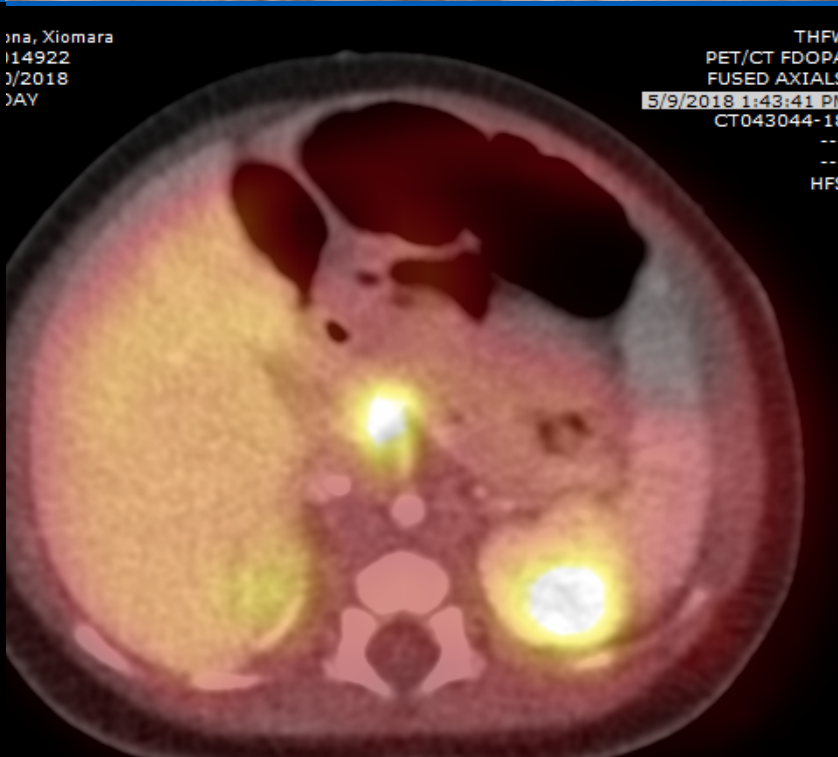


5/9/2018 1:43:41 PM

CT043044-18
--- 14922
--- 3/2018
HFS DAY

Z: 1
C: 128
W: 256

IM: 14 of 15 of 24

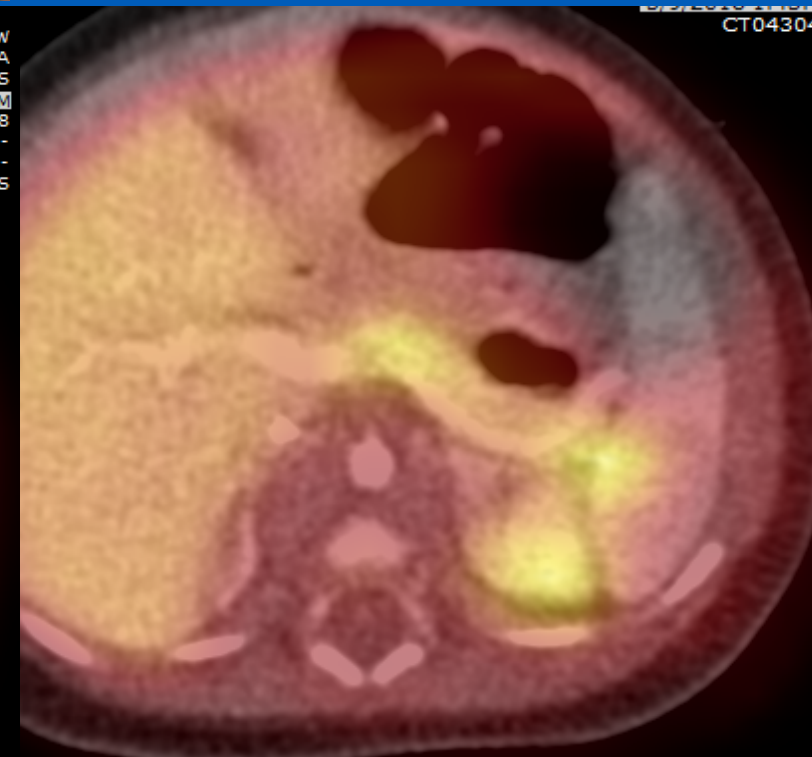


THFW
PET/CT FDOPA
FUSED AXIALS
5/9/2018 1:43:41 PM
CT043044-18

HFS

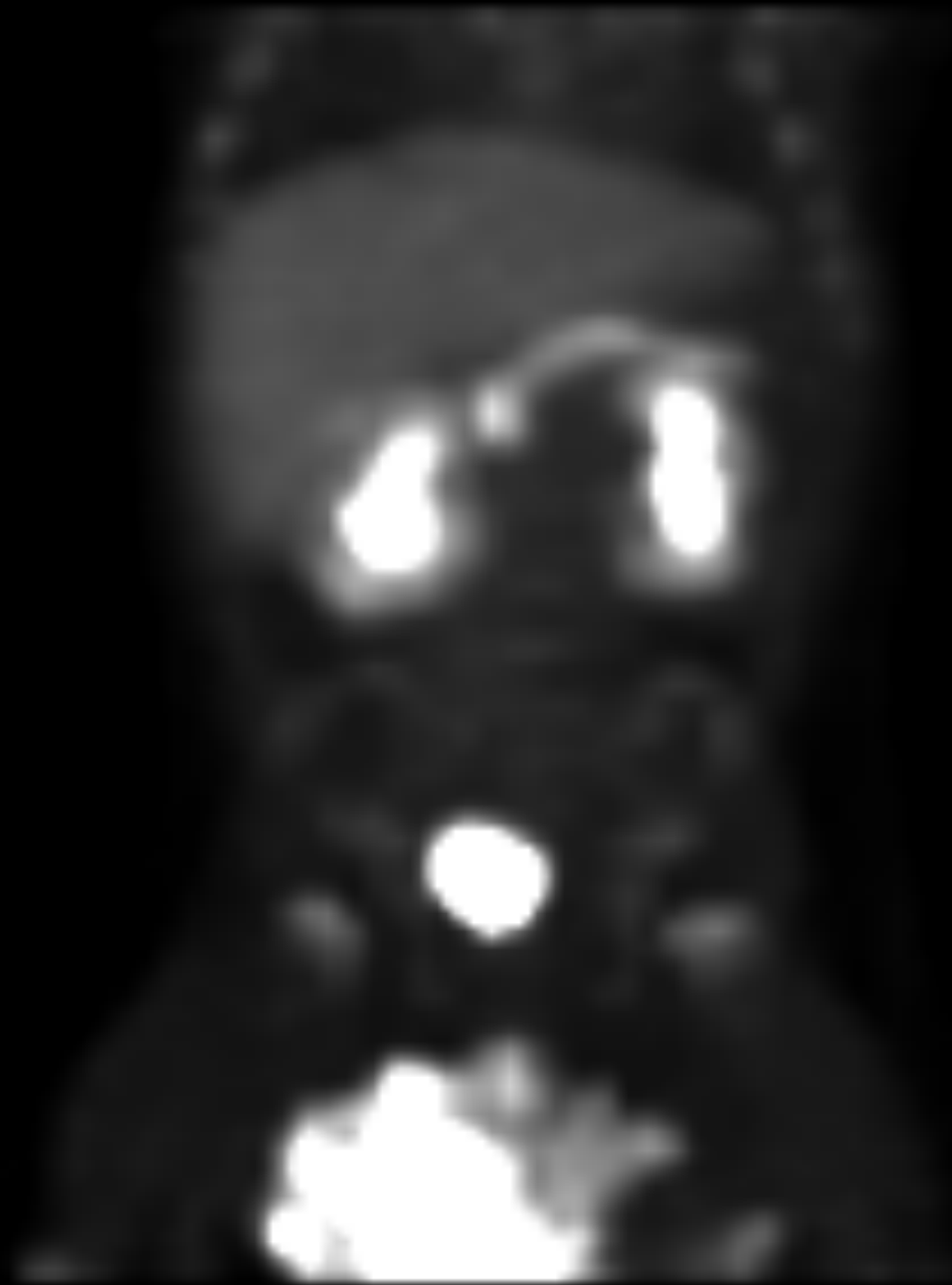
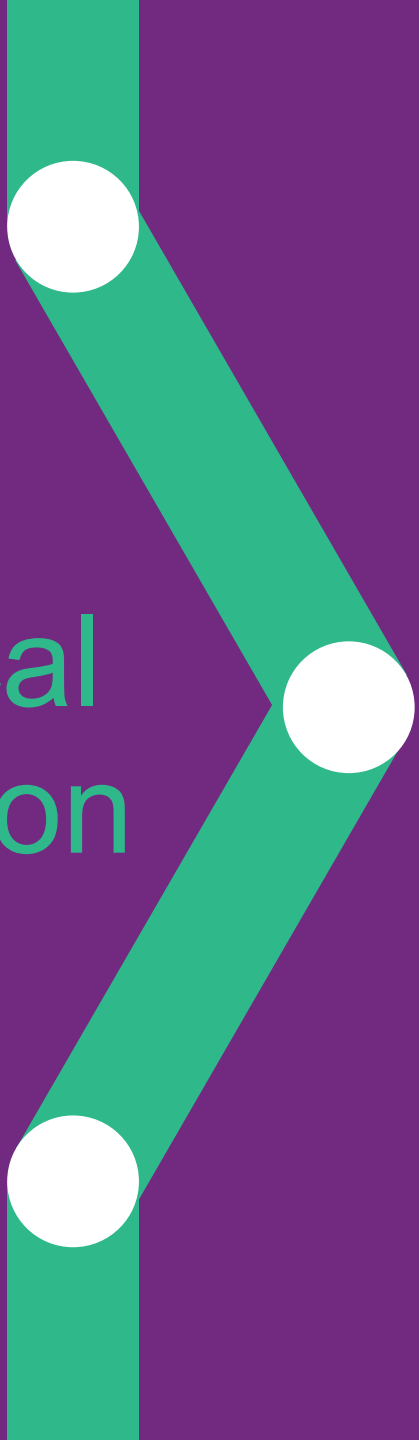Z: 1
C: 128
W: 256

IM: 15

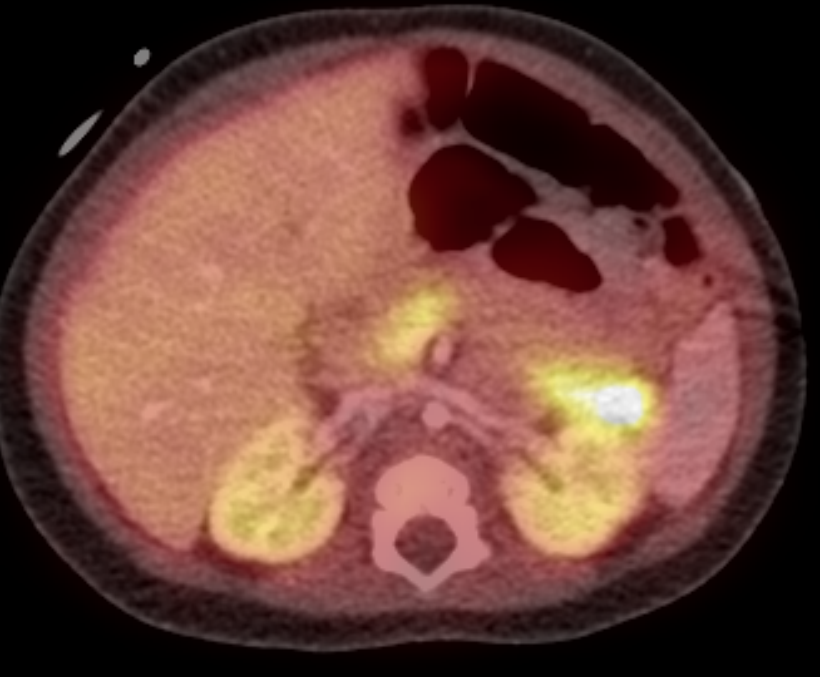
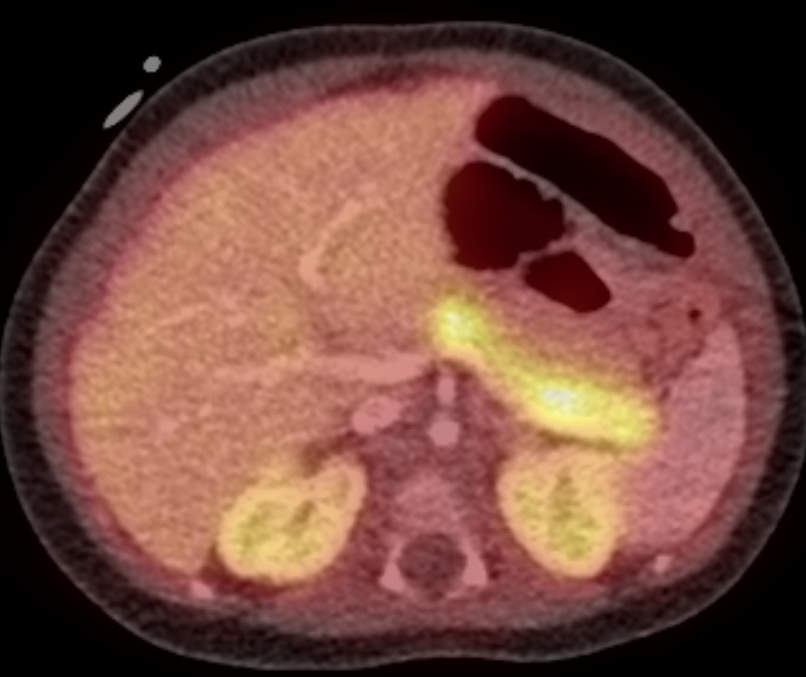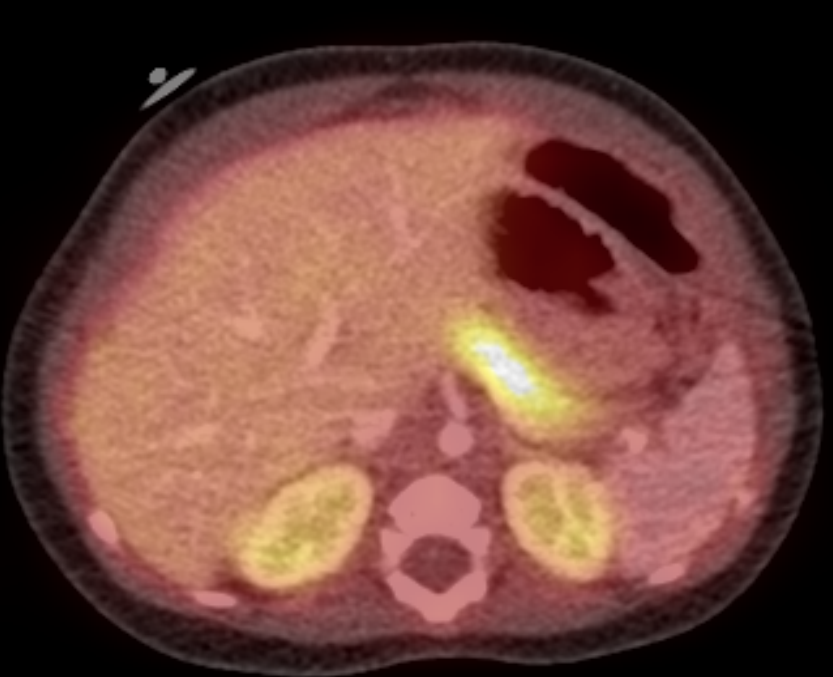
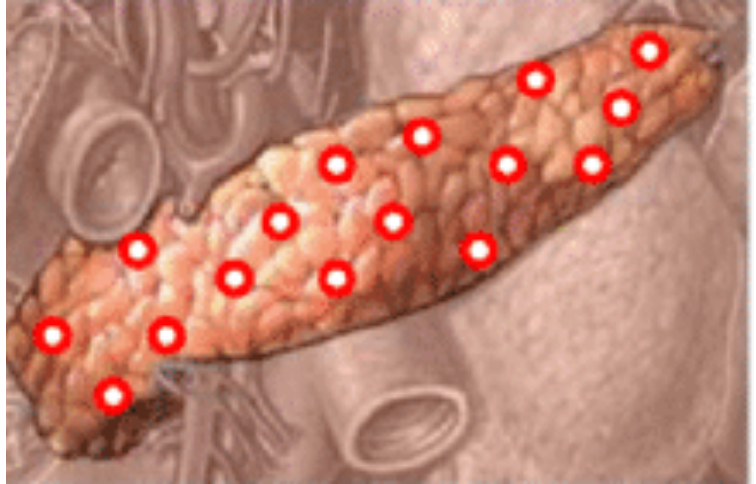



CT043044-18


Focal
Lesion



CHI - Diffuse

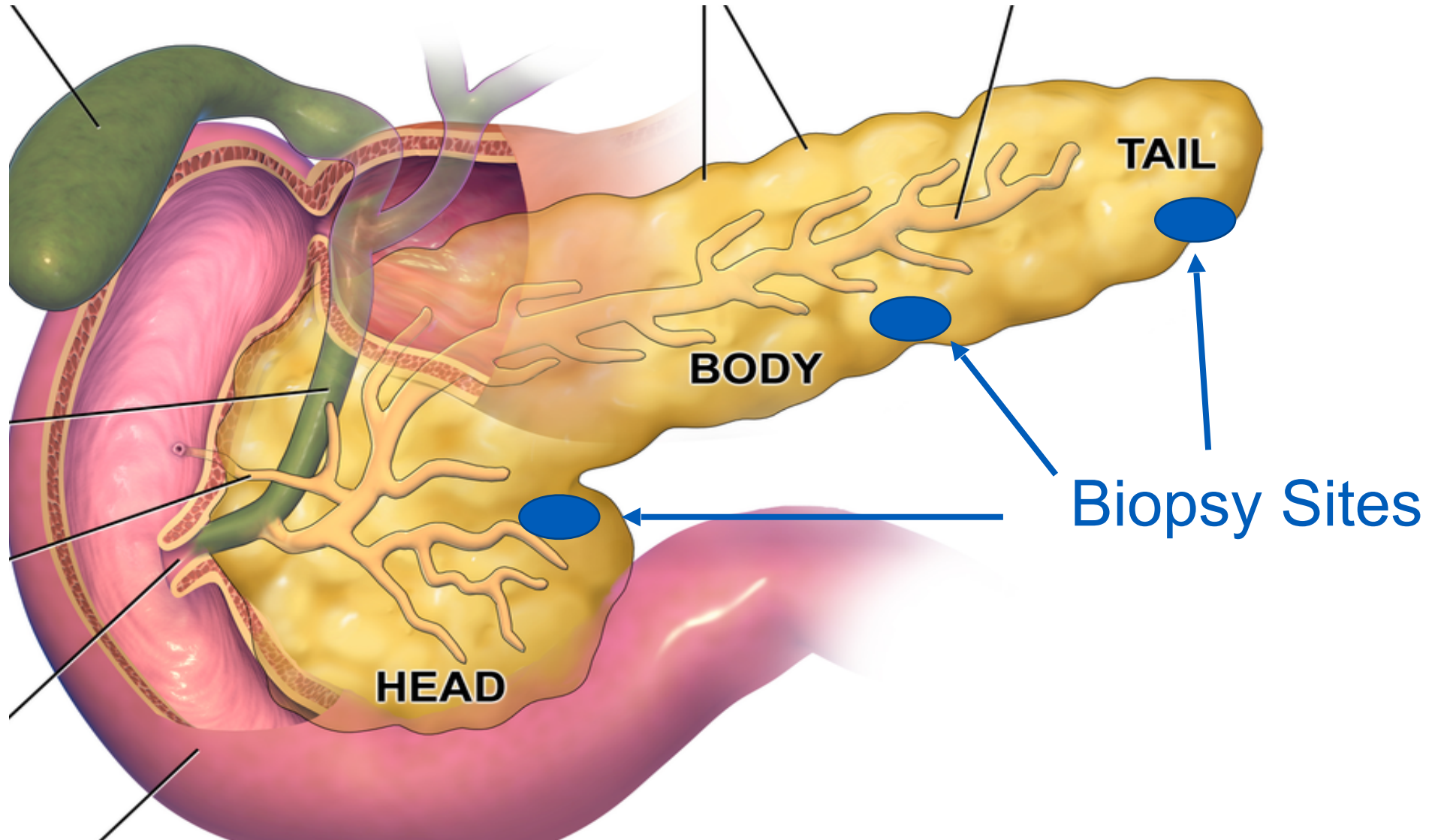


Focal CHI - Surgery


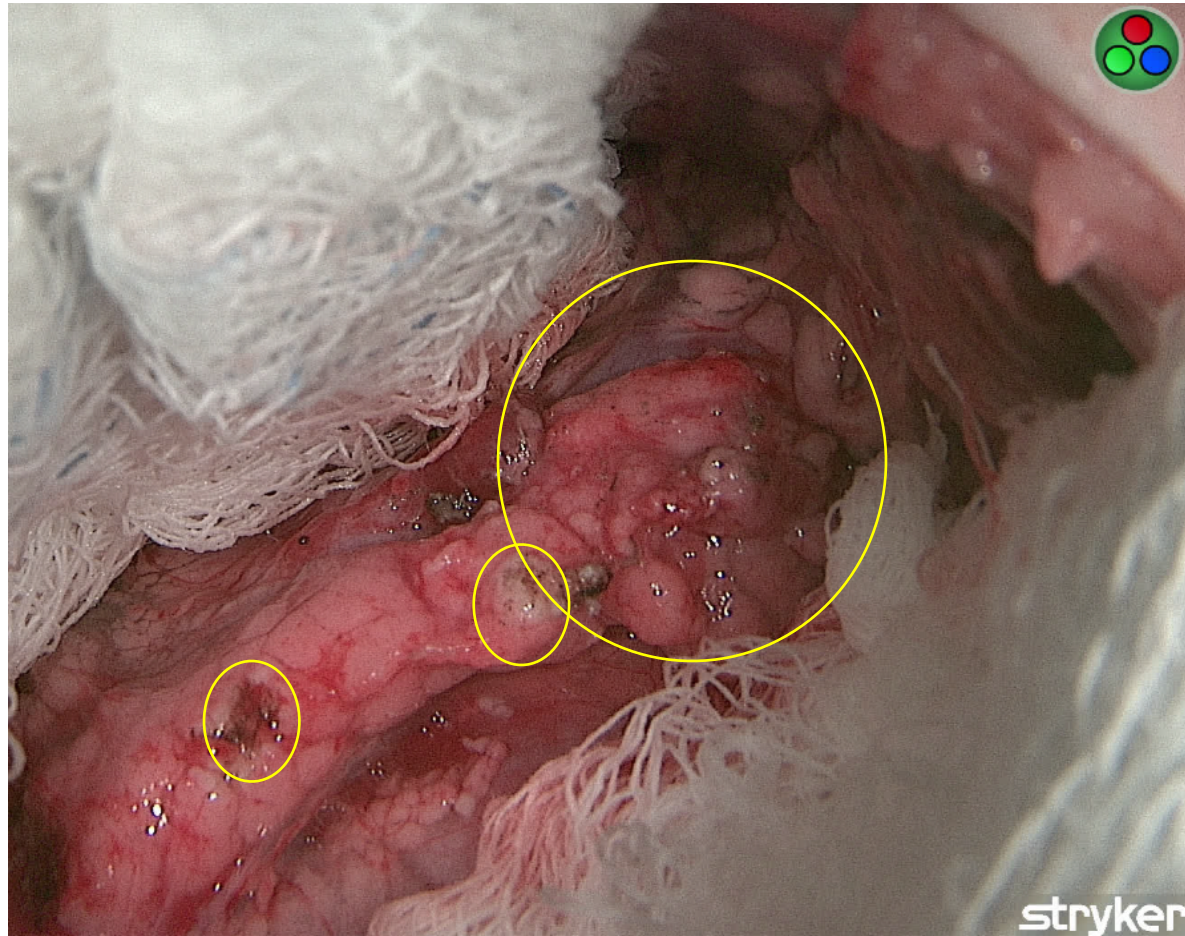


Visually inspect
Manual palpation
Ultrasound
ICG Green
Fully mobilize pancreas
Biopsy

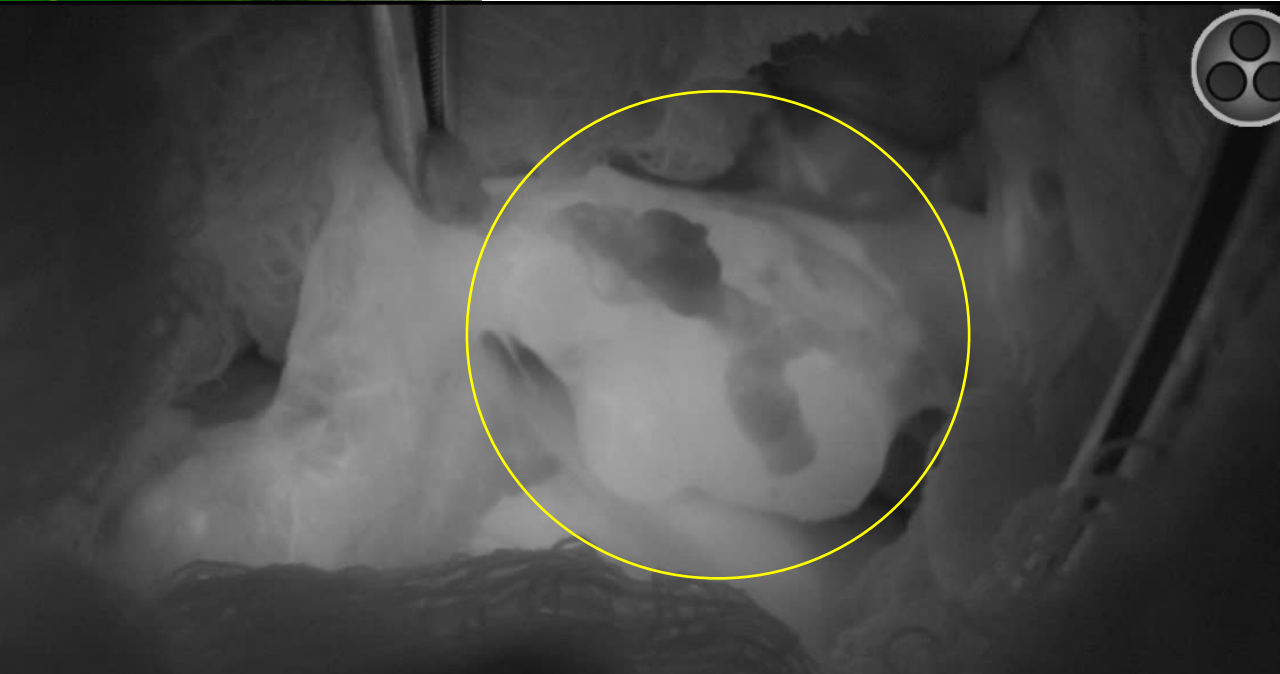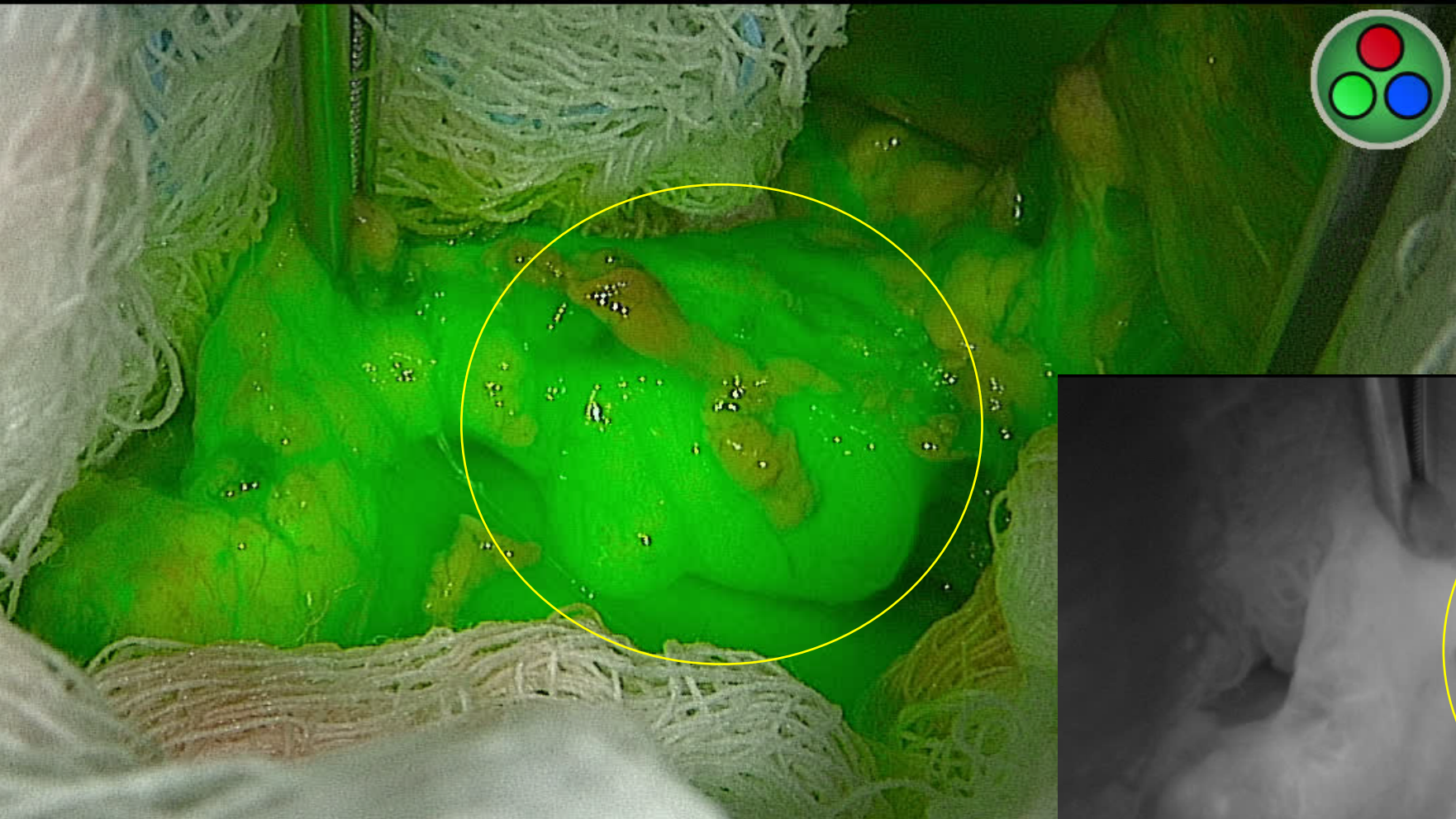
Biopsy



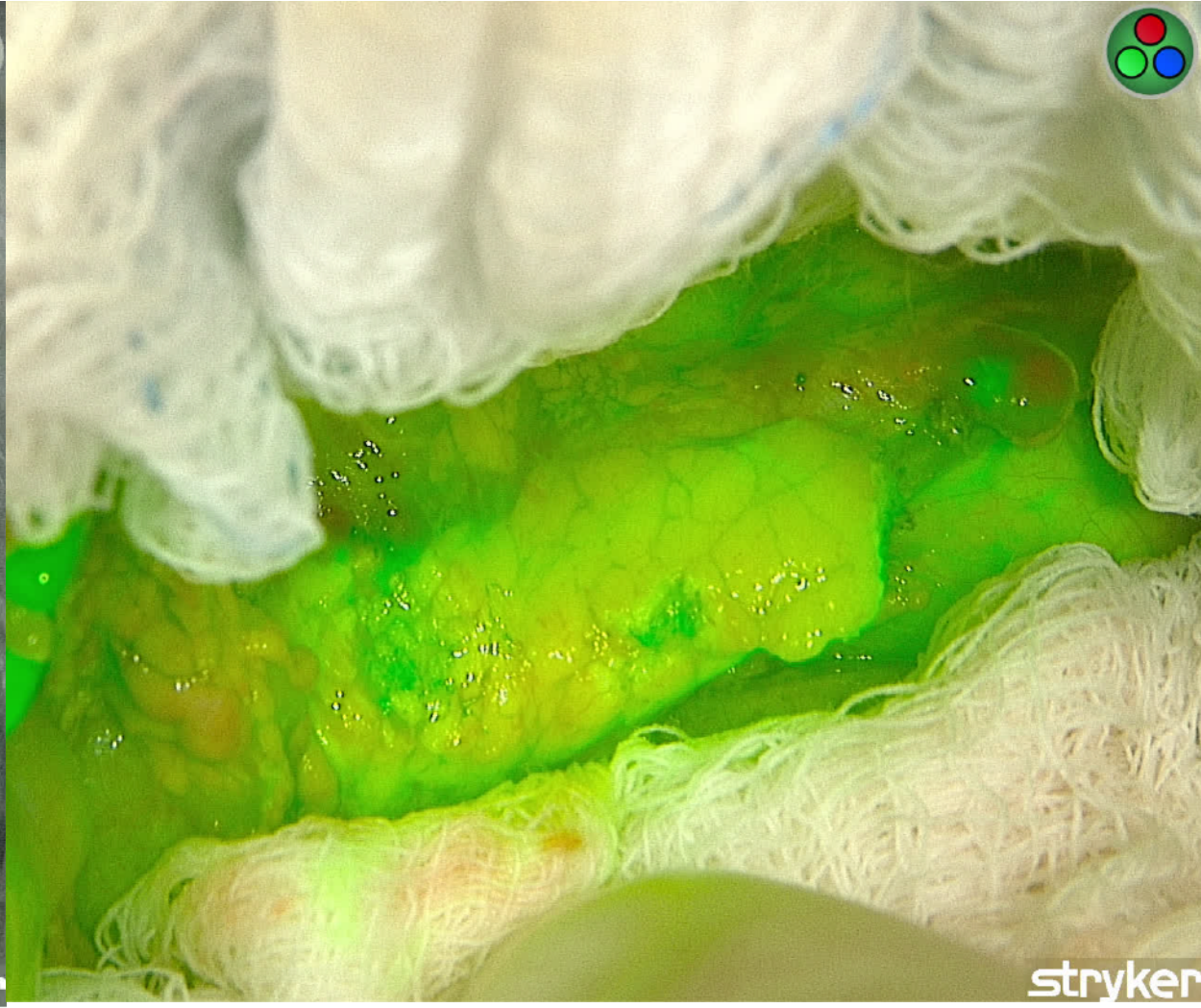ICG



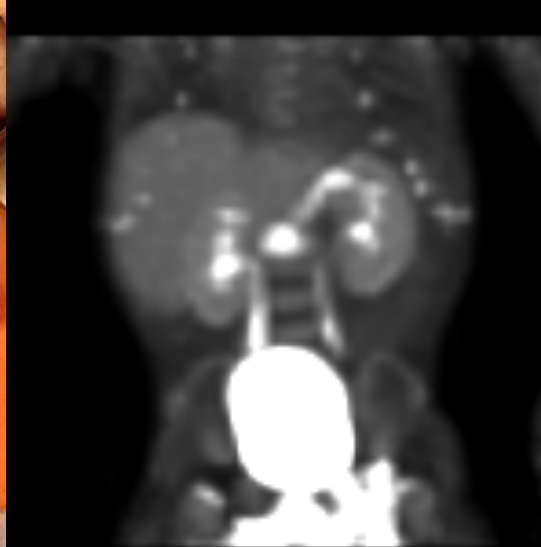
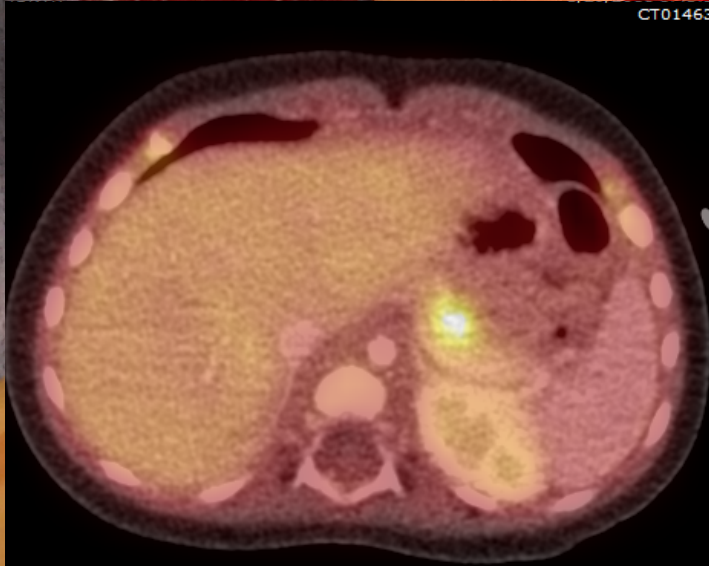
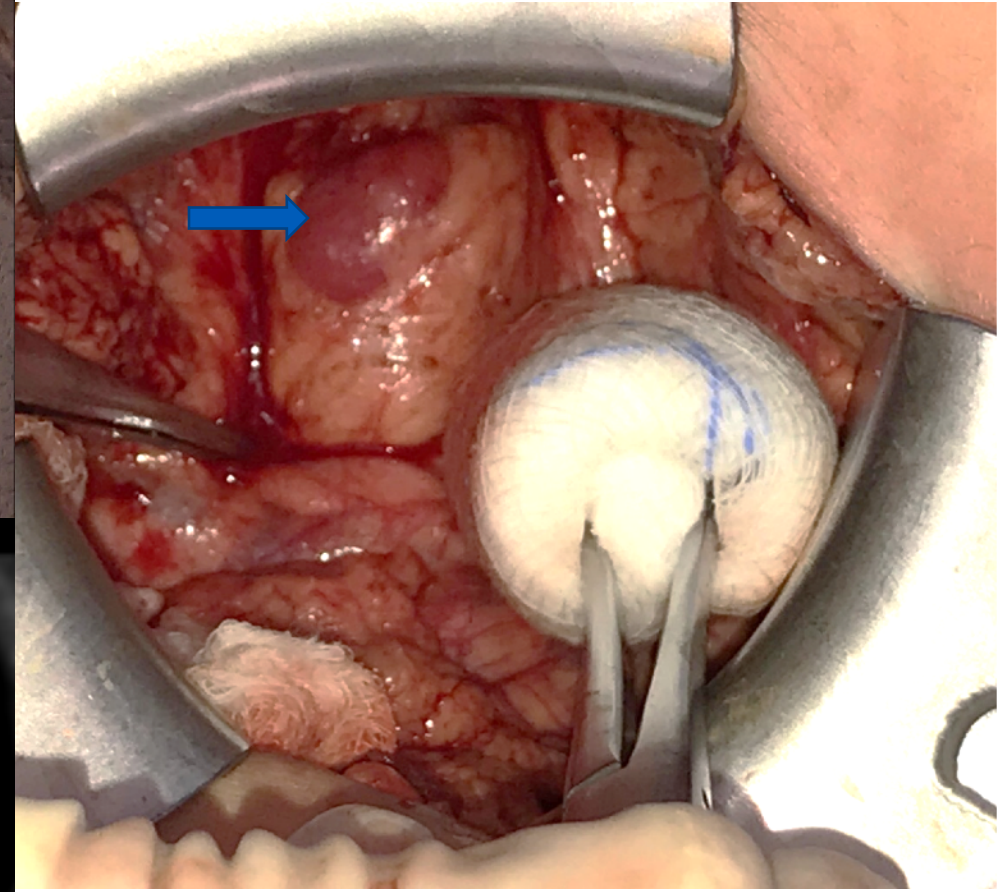
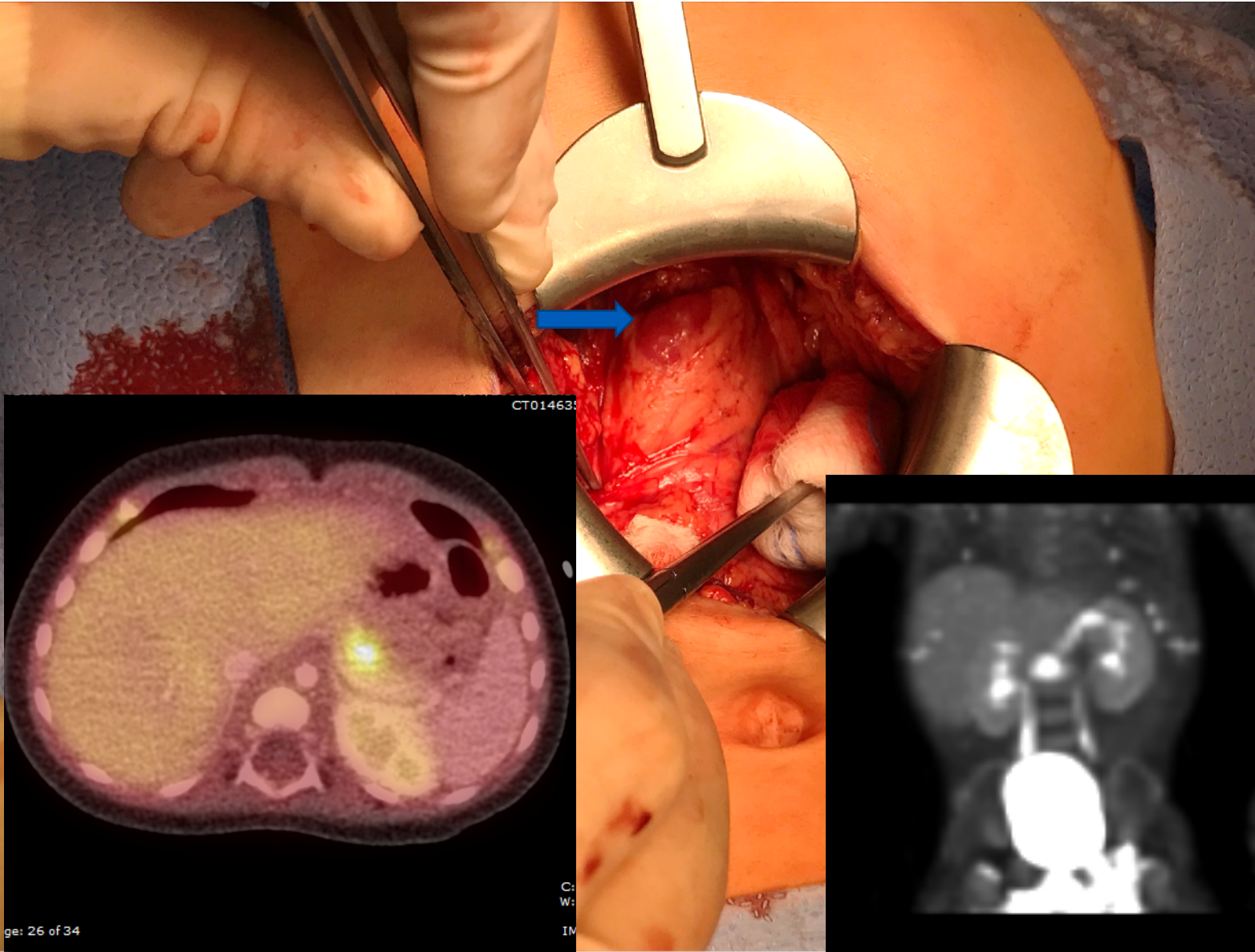
ICG

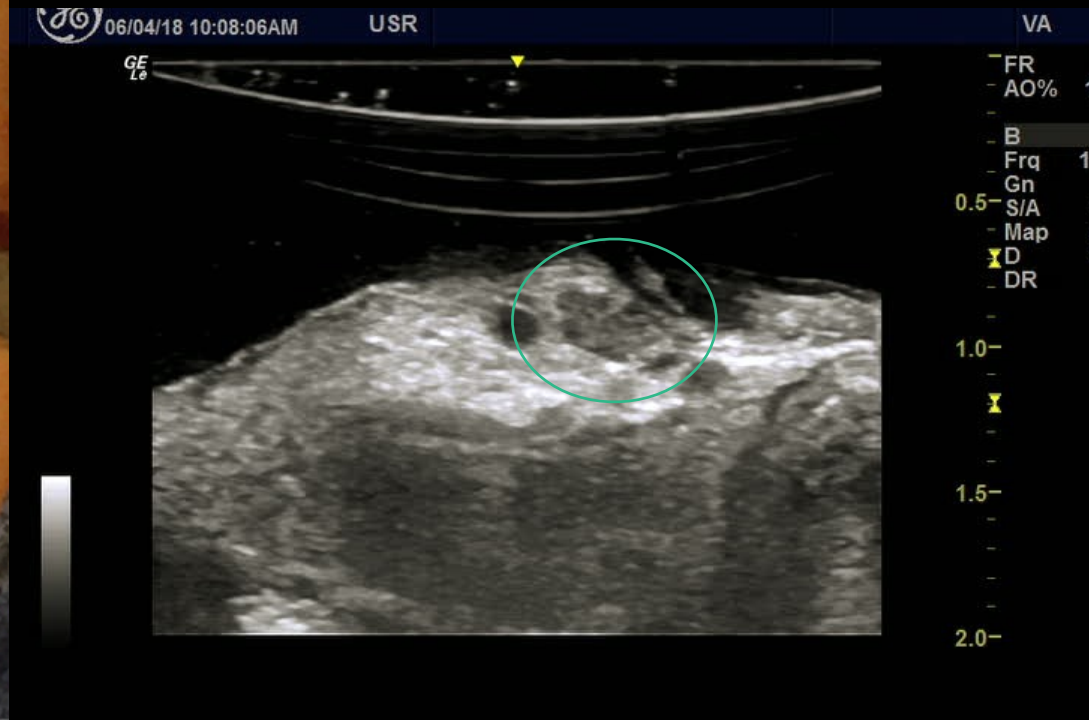
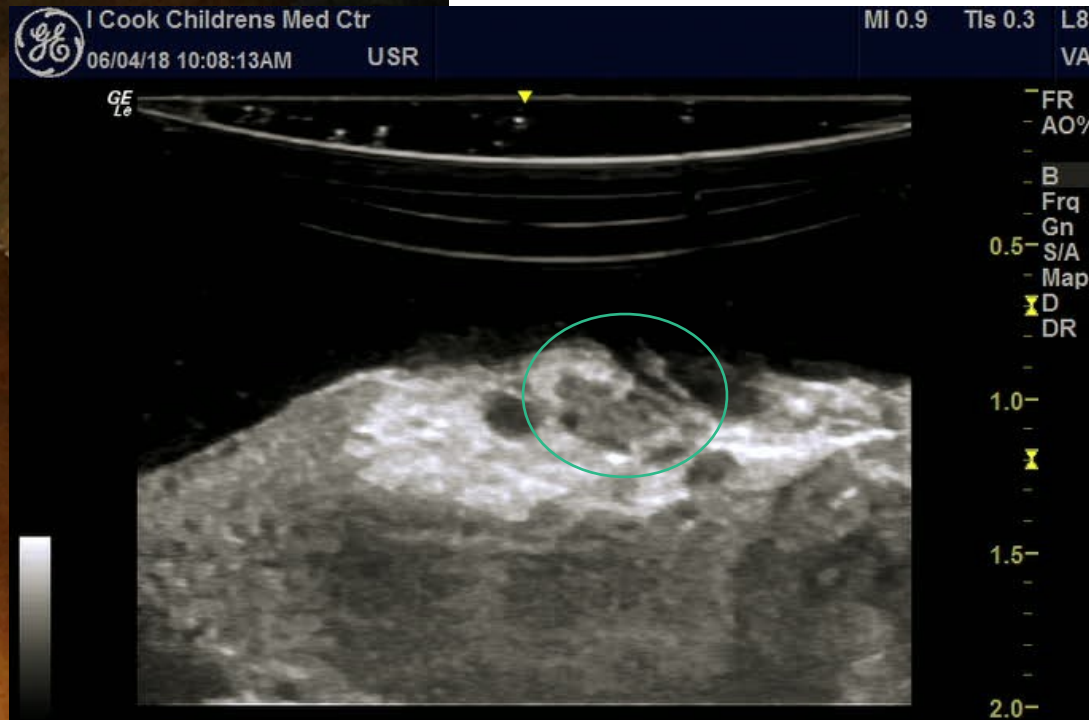
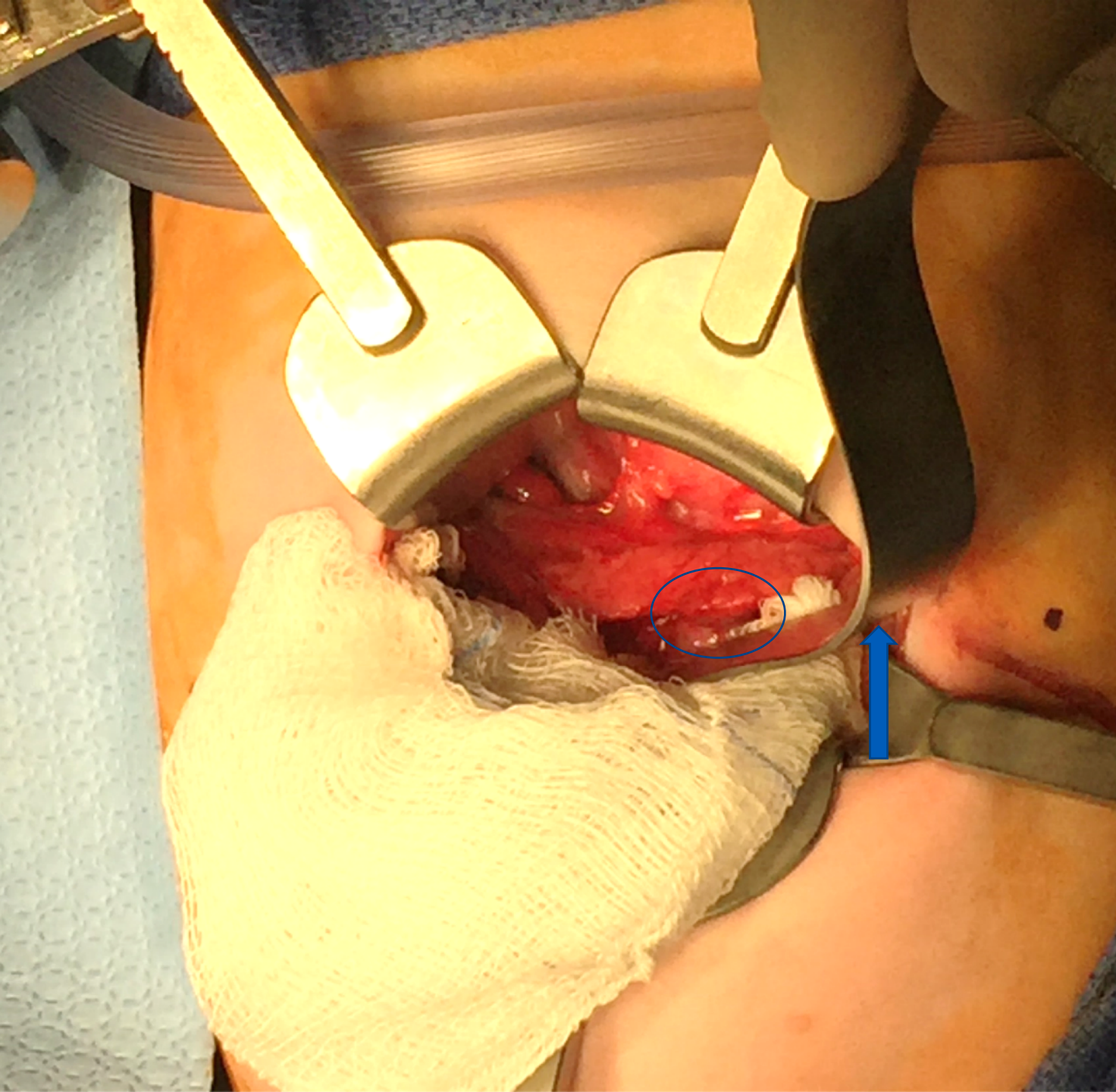


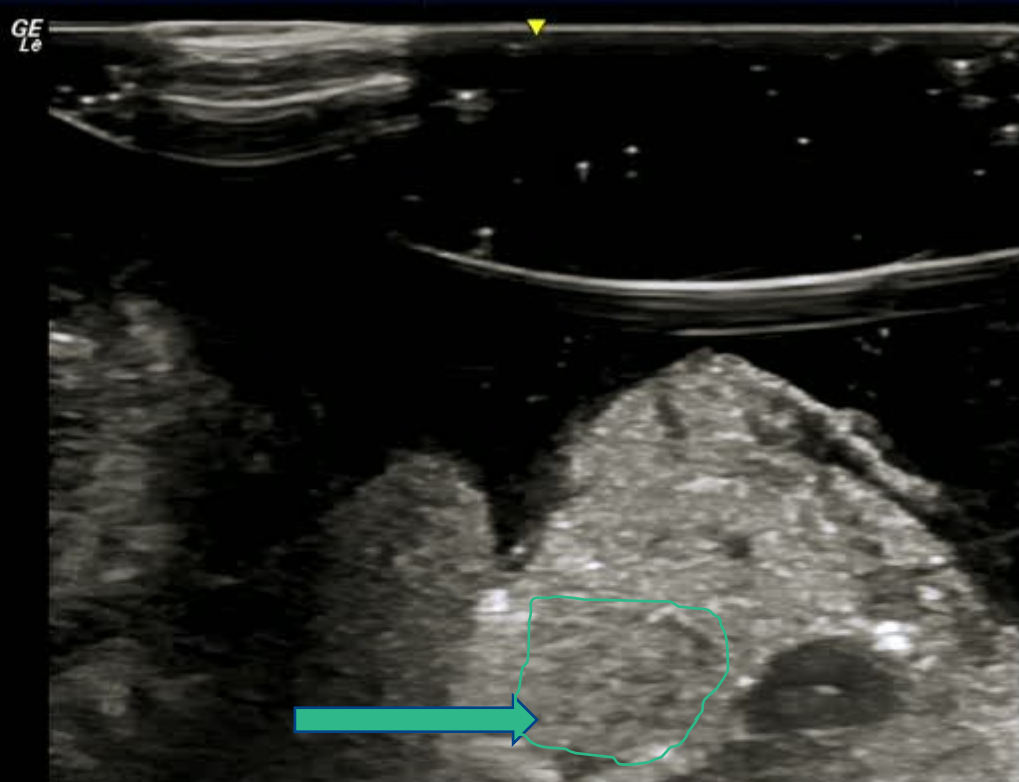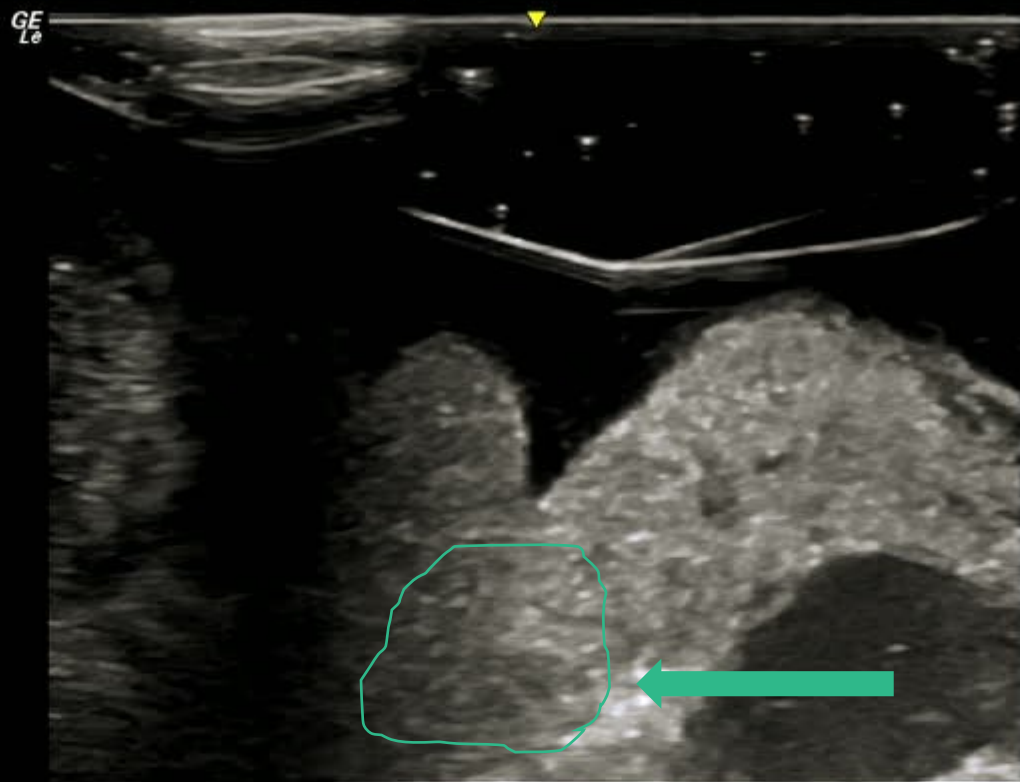ICG



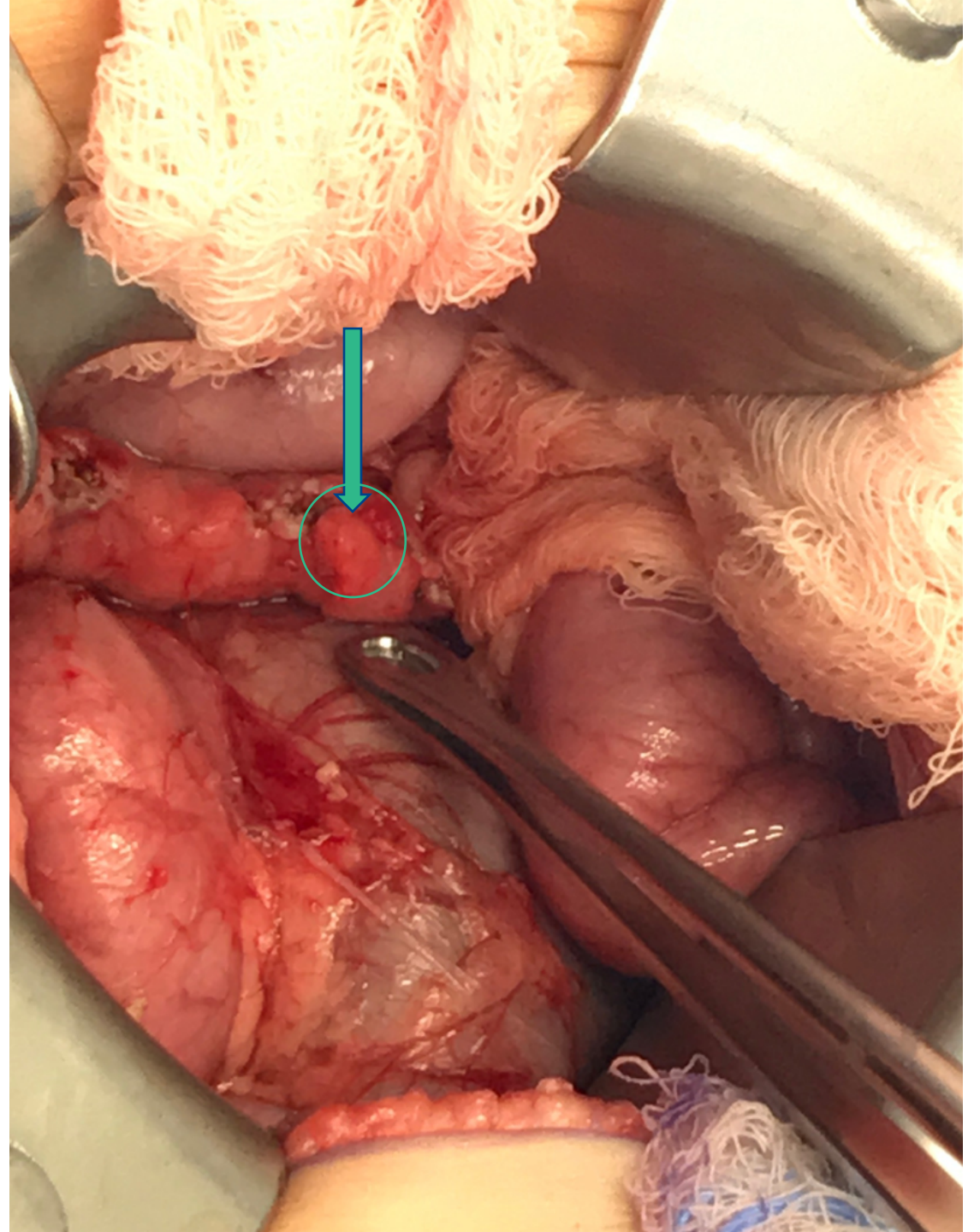
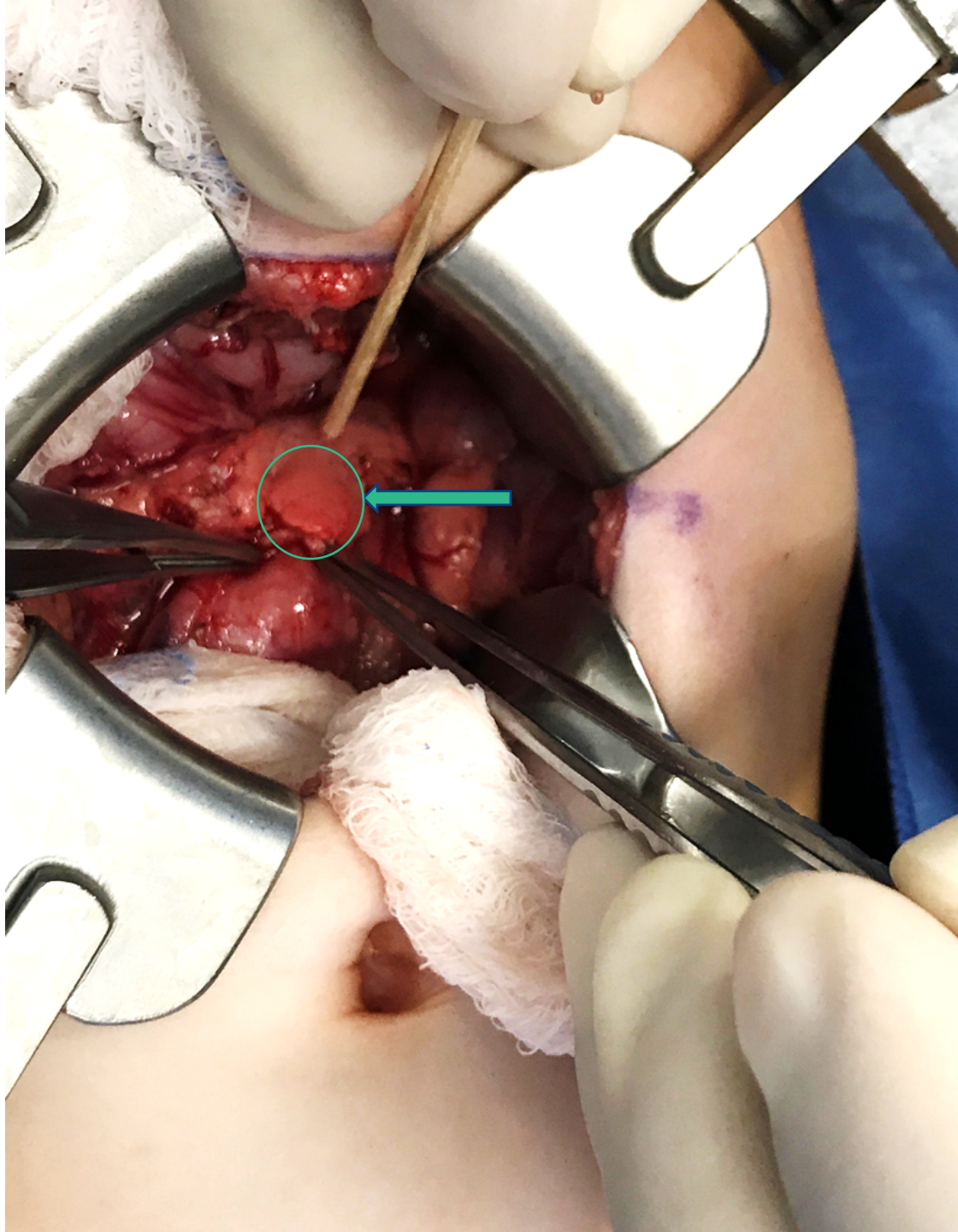
Focal CHI "Enucleation"



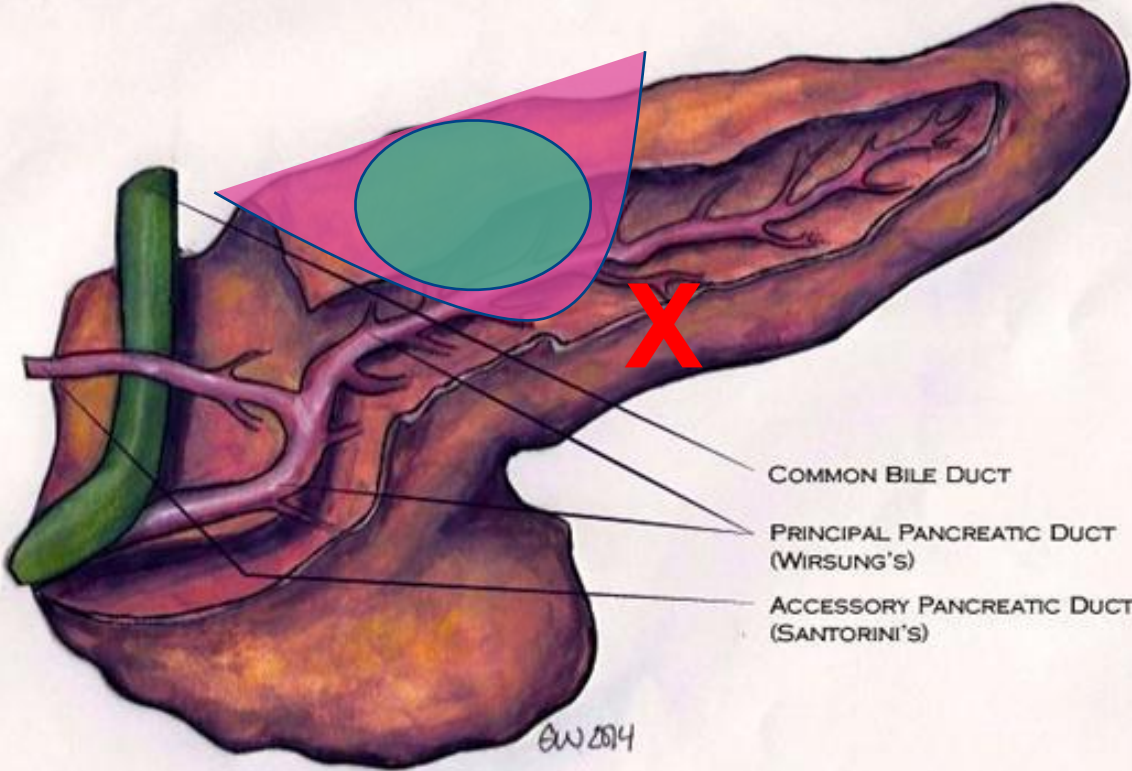
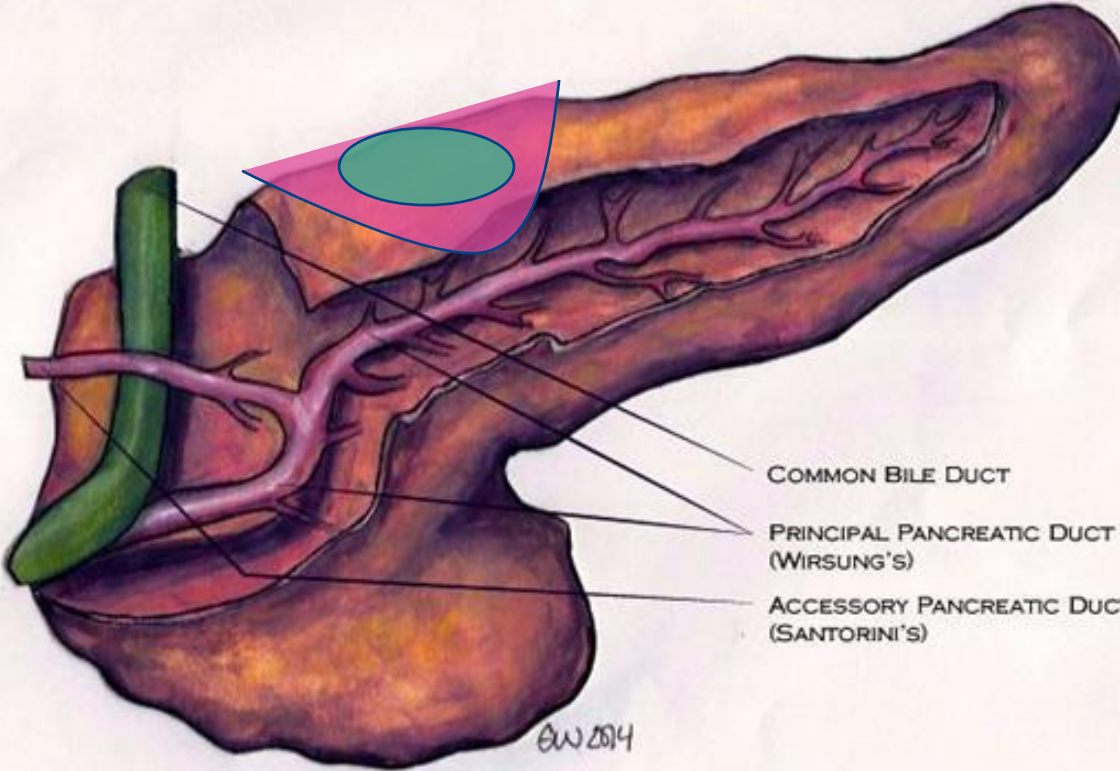




FR
- AOS
- B
- Frq
- Gn
0.5- S/A
- Map
- D
- DR
1.0-
1.5-
2.0-

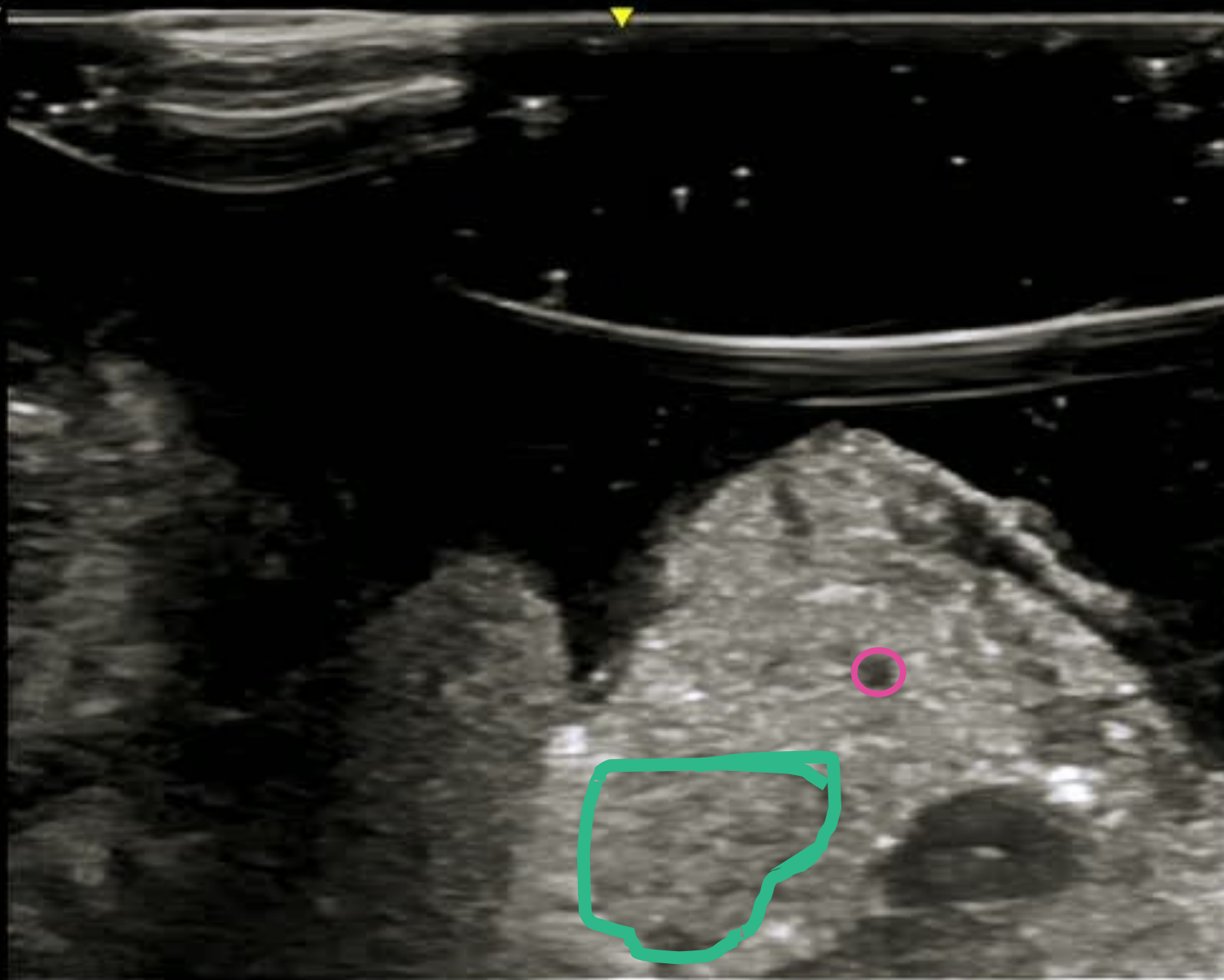


Watch out for the duct





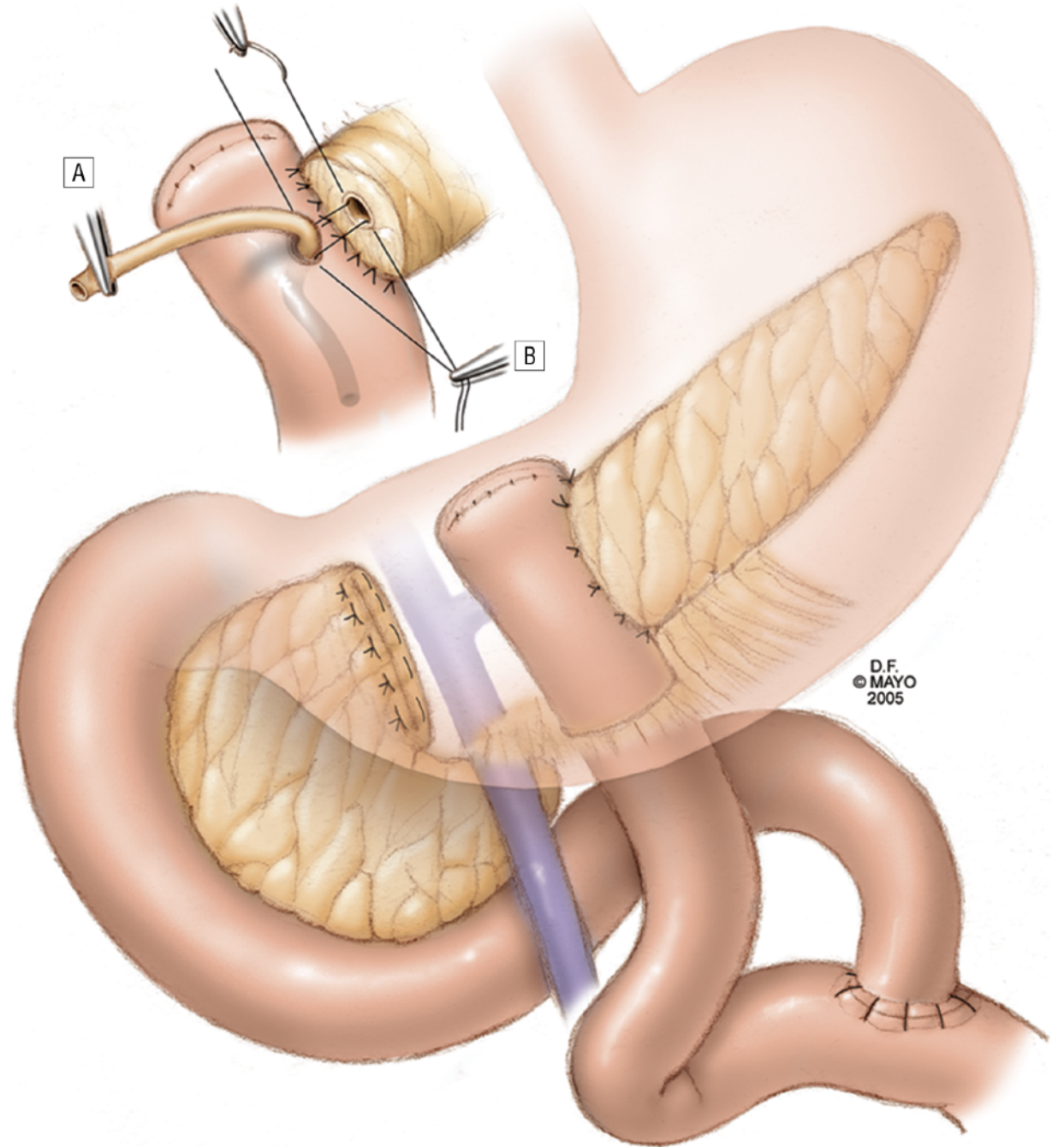
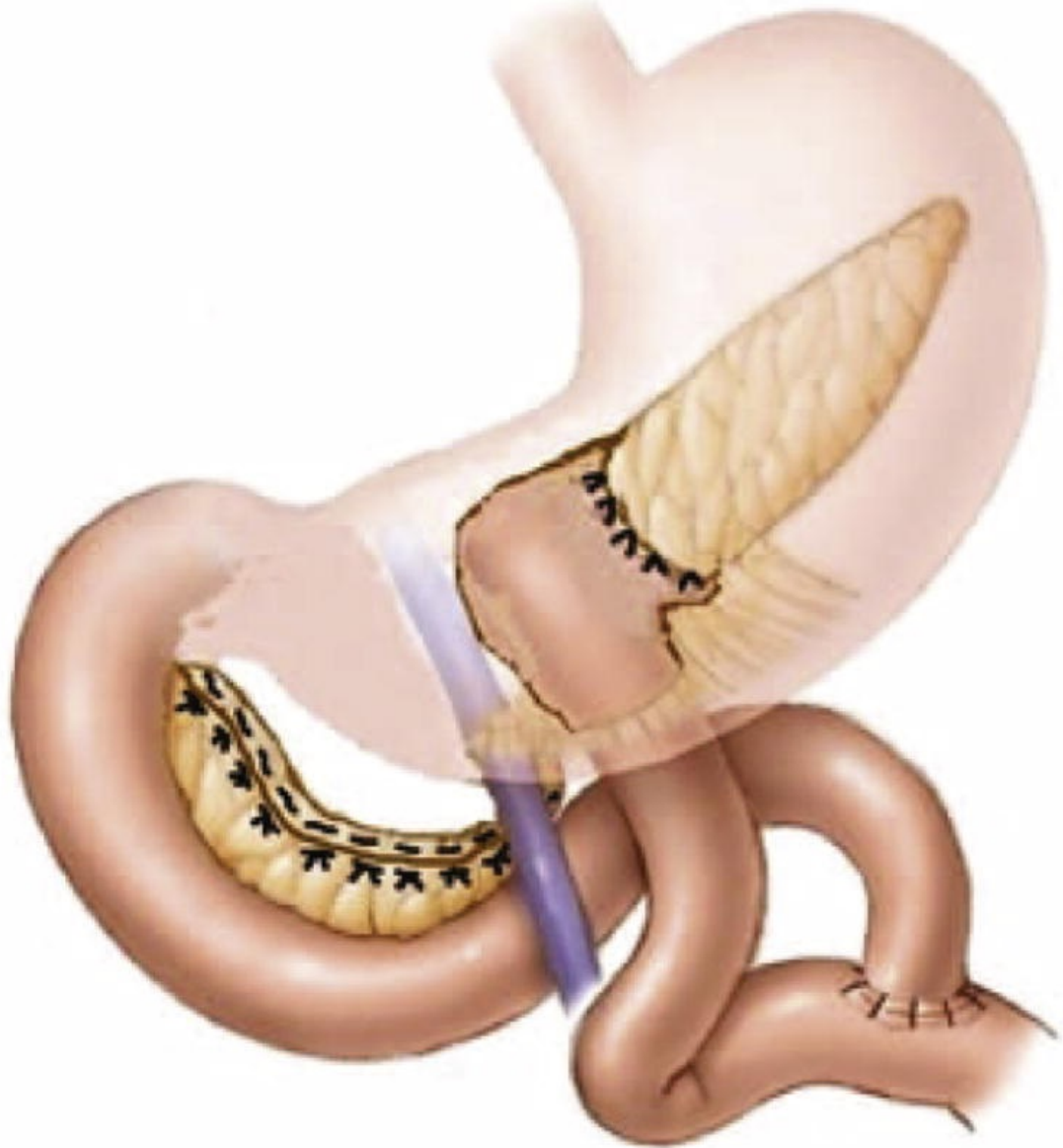
GE
Le



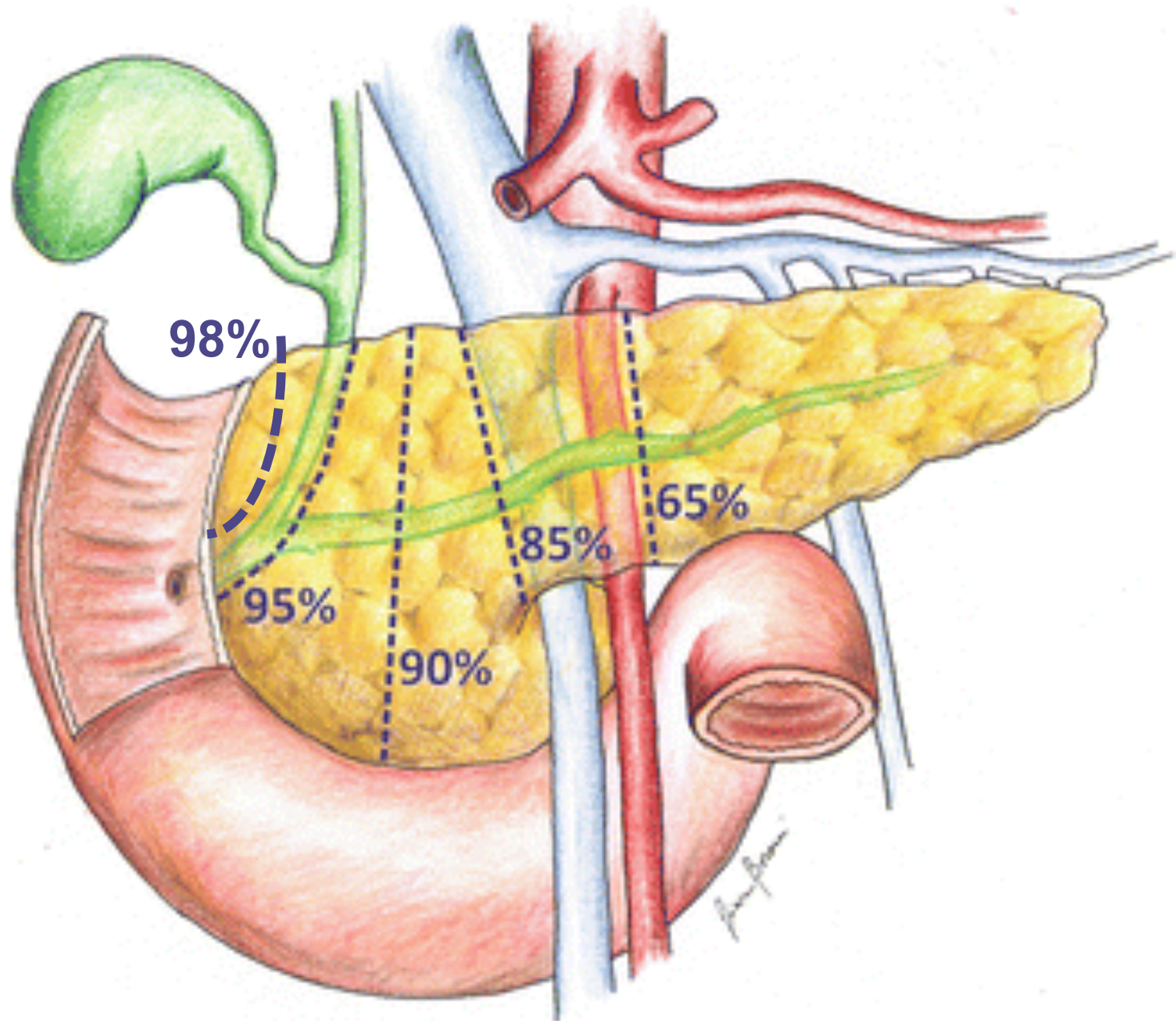
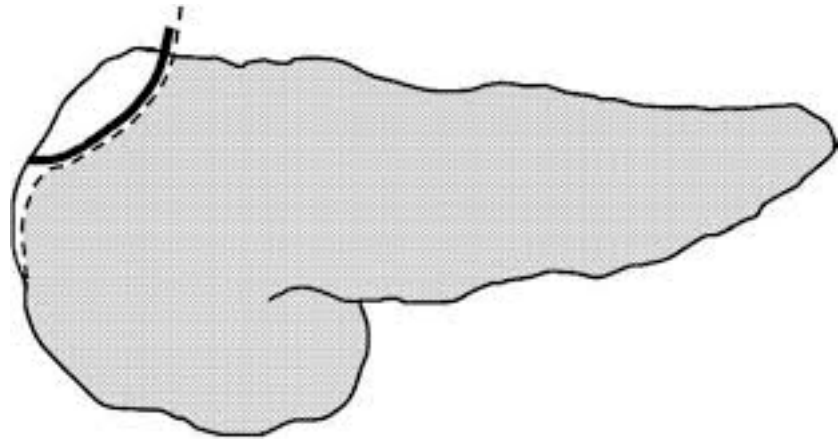
FR
AO°
B
Frq
Gn
0.5- S/A
- Map
D
DR
1.0-
1.5-
2.0-



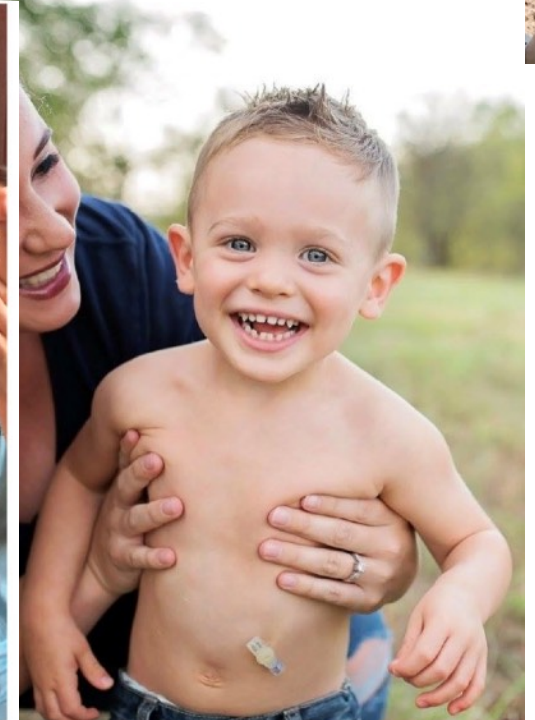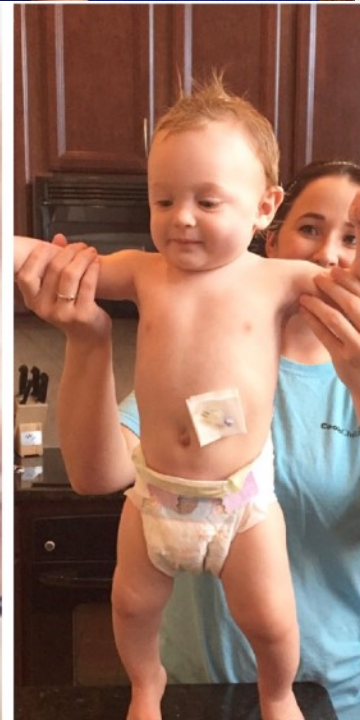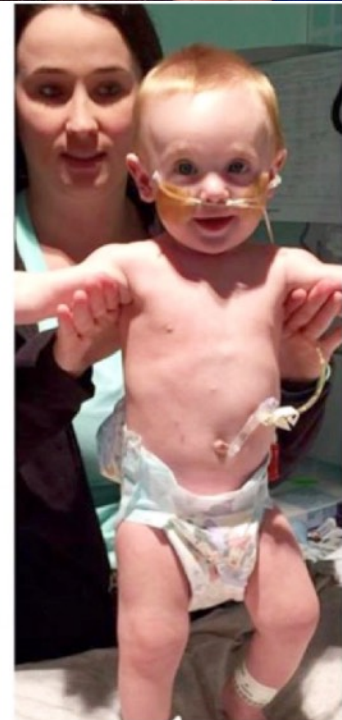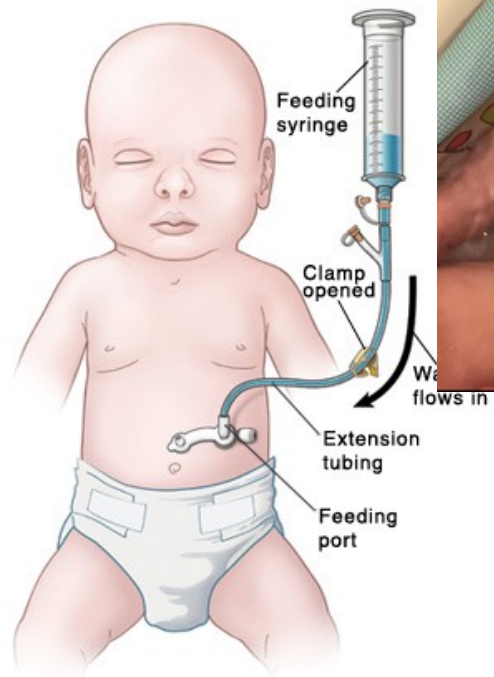
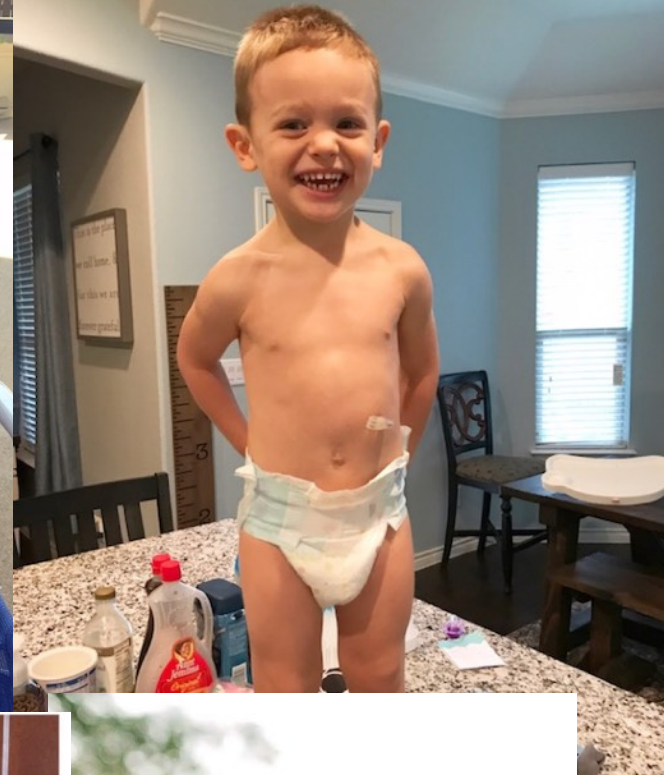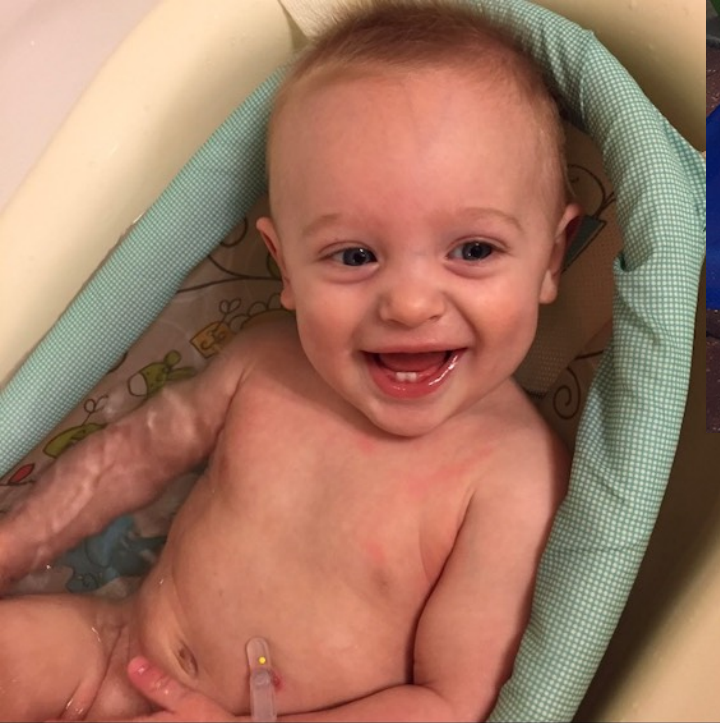Roux-en-Y



Diffuse CHI



Diffuse CHI



Post Op Recovery

Recovery of GI function -- usually 2-10 days

Post op pain

Anastomotic healing

Drain removal

Blood glucose levels

Complications

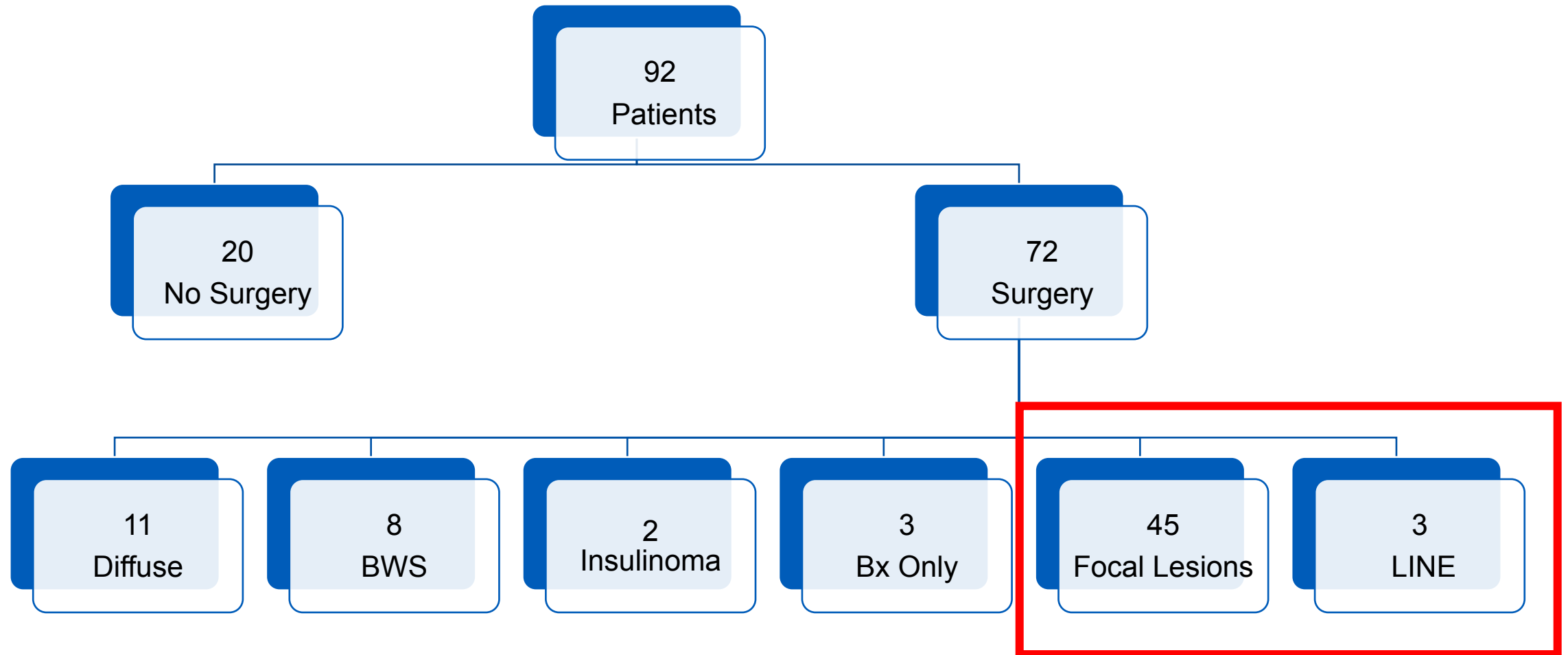
Complication	Number
Pancreatic Leak	1 (possible)
Pancreatitis	0
Recurrent Hyperinsulinism	20 (Mostly Diffuse pts)
Diabetes	6
Dumping syndrome	0
Feeding Intolerance	4
Bowel obstruction	0
Damage to Bile Duct	5
Damage to/loss of Spleen	1

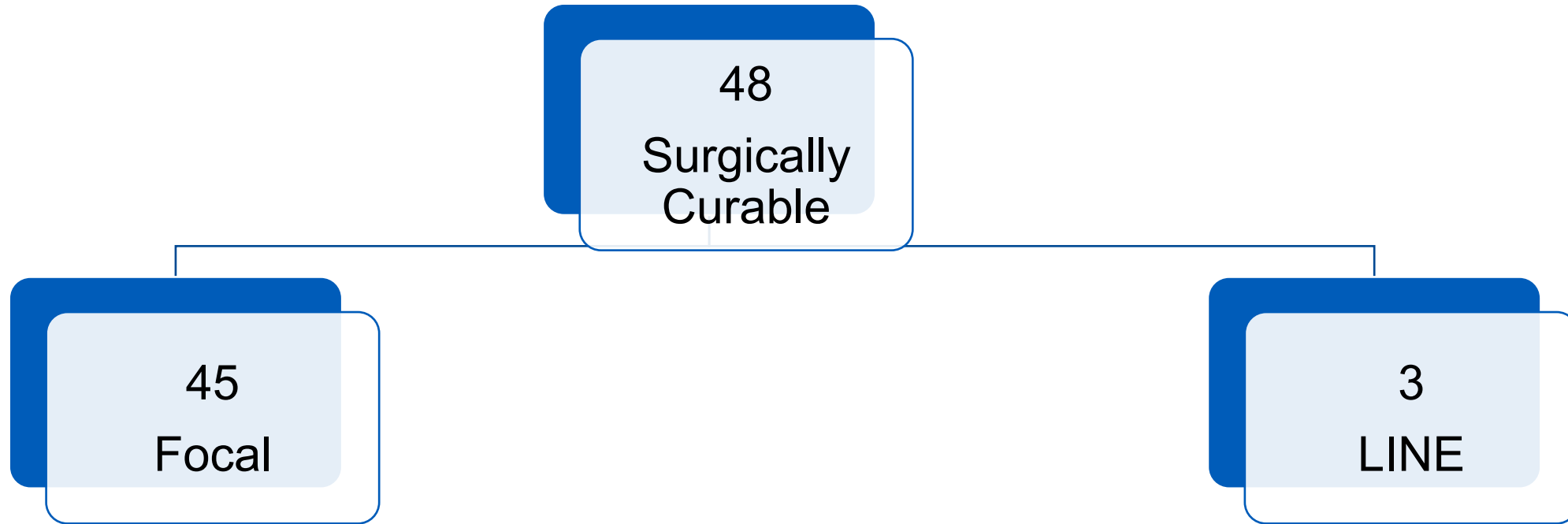
CCMC Experience Pre 18-F DOPA

Pre-Multi Disciplinary Team Approach					
Patient #	1	2	3	4	5
Age at Admission	67 days	5 days	9 days	7 days	70 days
Type of HI	Focal	Focal	Diffuse	Diffuse	Diffuse
% panc.	98	~60	98	95	98
Glycemic Outcome	Transient Diabetes	Hypoglycemia	Hypoglycemia	Hypoglycemia	Hypoglycemia
Long Term Outcome	Cured	Hypoglycemia	Diabetes	Diabetes	Diabetes
Length of Stay	53	50	41	60	36
Complication	No	No	No	No	No
Feeding Tube Dependent	No	No	No	No	No

1/5 cured
 4/5 ongoing hypoglycemia
 3/5 Diabetes

CCMC Experience with 18-F DOPA





- **40 Cured**
- **2 Hypoglycemic – Unable to find the lesion**
- **2 Eating Normal/ Not on meds but not cured**

3 Cured

93% Cure Rate

Questions?

Chip Uffman
cookchildrens.org